



**Kaiser Foundation Health Plan
of Washington**

**Clinical Review Criteria
Positron Emission Tomography (PET) Scan**

NOTICE: Kaiser Foundation Health Plan of Washington and Kaiser Foundation Health Plan of Washington Options, Inc. (Kaiser Permanente) provide these Clinical Review Criteria for internal use by their members and health care providers. The Clinical Review Criteria only apply to Kaiser Foundation Health Plan of Washington and Kaiser Foundation Health Plan of Washington Options, Inc. Use of the Clinical Review Criteria or any Kaiser Permanente entity name, logo, trade name, trademark, or service mark for marketing or publicity purposes, including on any website, or in any press release or promotional material, is strictly prohibited.

Kaiser Permanente Clinical Review Criteria are developed to assist in administering plan benefits. These criteria neither offer medical advice nor guarantee coverage. Kaiser Permanente reserves the exclusive right to modify, revoke, suspend or change any or all of these Clinical Review Criteria, at Kaiser Permanente's sole discretion, at any time, with or without notice. **Member contracts differ in health plan benefits. Always consult the patient's Evidence of Coverage or call Kaiser Permanente Member Services at 1-888-901-4636 (TTY 711), Monday through Friday, 8 a.m. to 5 p.m. to determine coverage for a specific medical service.**

**Criteria
For Medicare Members**

Source	Policy
CMS Coverage Manuals	None
National Coverage Determinations (NCD)	<p>Positron Emission Tomography (PET) Scans (220.6) (General) <i>Effective January 1, 2022, the Centers for Medicare & Medicaid Services removed the umbrella national coverage determination (NCD) for Positron Emission Tomography (PET) Scans. In the absence of an NCD, coverage determinations for all oncologic and non-oncologic uses of PET that are not included in another NCD under section 220.6 will be made by the Medicare Administrative Contractors under section 1862(a)(1)(A) of the Social Security Act. All PET indications currently covered or non-covered under NCDs under section 220.6 remain unchanged and MACs shall not alter coverage for indications covered under NCDs.</i></p> <p>*Refer to the Noridian Local Coverage Article (A54668) listed below for coverage indications for specific radiopharmaceuticals.</p> <ul style="list-style-type: none"> • PET for Perfusion of the Heart (220.6.1) (includes PET stress) • FDG PET for Myocardial Viability (220.6.8) • FDG PET for Refractory Seizures (220.6.9) • FDG PET for Dementia and Neurodegenerative Diseases (220.6.13) • Positron Emission Tomography (FDG) for Oncologic Conditions (220.6.17) • Positron Emission Tomography (NaF-18) to Identify Bone Metastasis of Cancer (220.6.19) (not covered per Medicare NCD) • Beta Amyloid Positron Tomography in Dementia and Neurodegenerative Disease (220.6.20)
Local Coverage Determinations (LCD)	None
Local Coverage Article*	<p>Positron Emission Tomography Scans Coverage (A54668) *Documents coverage indications for PET scans and radiopharmaceuticals including but not limited to: A9587 Gallium GA-68 Dotatate (neuroendocrine tumors) A9515 Choline C-11, diagnostic (prostate cancer) A9588 Fluciclovine F-18 (Axumin PET - prostate) A9593, A9594, A9496, A9800 Gallium GA-68 PSMA-11 (PSMA PET – a) A9595 Piflufolastat F-18 (PSMA PET – prostate) A9602 Fluorodopa F-18 (Brain PET—Parkinsons)</p>

For Non-Medicare Members

No Oncologic Diagnosis Confirmed

In the absence of a confirmed oncological diagnosis, PET results may be needed to determine the optimal location to perform an invasive diagnostic procedure due to difficulty accessing potential biopsy sites because of anatomical complexity as described in the medical records.

Solitary Pulmonary Nodule (SPN) Solid or Part Solid	Indications
	1) Newly discovered, without known prior malignancy; and the following are met: <ol style="list-style-type: none"> a) A concurrent thoracic CT has been performed AND b) A single indeterminate or possibly malignant lesion more than 0.8 cm in diameter has been detected AND c) Not recommended for ground glass opacities/nodules 2) The purpose of the scan is to determine likelihood of malignancy in order to plan management of care

Oncological Diagnosis Confirmed

For patients with a biopsy proven or confirmed oncologic diagnosis (typically biopsy proven), PET scans may be medically necessary for any of the listed diagnoses below when standard staging/restaging diagnostic and imaging studies are inconclusive AND further characterization is needed to make management decisions. The expected change in clinical management must be documented in the clinical records. The grid below contains the letters TNM. T is for tumor and the number associated describes the tumor. N is for lymph node involvement. M is for extent of metastasis.

Oncological Diagnosis	Indications
Anal	1) New diagnosis – consider PET scan for staging of T3 – T4, N0; or with any T, node positive
Breast Cancer	1) Stage I, II: PET scan is not recommended 2) Stage III A or B: PET scan is not recommended for operable stage III. May be helpful in non operable stage III if equivocal findings on CT and bone scans 3) Stage IV: PET not routinely covered but may be indicated if conventional imaging is equivocal and results will change management 4) The following indications are not covered for PET scans <ol style="list-style-type: none"> a) Routine surveillance b) Initial diagnosis of breast cancer and the staging of axillary lymph nodes
Cervical	<u>Staging for Invasive Cervical Cancer as an Adjunct to Conventional Imaging:</u> An FDG PET scan is reasonable and necessary for the detection of metastases during the pre-treatment management phase (i.e., staging) in patients with newly diagnosed locally advanced cervical cancer with no extra-pelvic metastasis on conventional imaging tests, such as computed tomography (CT) or magnetic resonance imaging (MRI). Use of FDG PET as an adjunct may more accurately assist in the non-invasive detection of para-aortic, pelvic nodal involvement and other metastases in the pre-treatment phase of disease. The following conditions must be met: <ol style="list-style-type: none"> 1) If stage is less than or equal to IB1: PET not routinely recommended 2) If stage is IB2 or greater: CT, PET scan or MRI as clinically indicated
Colorectal Cancer	1) Initial staging Colon cancer appropriate for resection: Not routinely indicated and should not supplant contrast-enhanced CT. <ol style="list-style-type: none"> a) PET may be indicated for metastatic adeno carcinoma of the large bowel when there is potentially surgically curable metastatic disease 2) Restaging <ol style="list-style-type: none"> a) When the post-operative carcinoembryonic antigen (CEA) or liver function tests (LFTs) remain elevated and other attempts at imaging are negative OR

Oncological Diagnosis	Indications
	b) Evaluation of a potentially resectable metastatic lesion in order to confirm that it is resectable and to confirm absence of other sites of disease OR c) Differentiating local tumor recurrence from post-operative and/or post-radiation scarring 3) Surveillance: not recommended 4) Monitoring therapy progress is not indicated
Esophageal	For staging and restaging 1) If no evidence of metastatic disease on chest/abdominal CT and 2) Individual is a candidate for aggressive therapy
Gastric/GE Junction	For staging and restaging (not necessary for T1 patients) 1) If no evidence of metastatic disease on chest/abdominal CT and 2) Individual is a candidate for aggressive therapy
Gastroenteropancreatic Neuroendocrine Tumors (GEP-NET)	Kaiser Permanente endorses the recommendations for PET imaging using somatostatin receptor (SSR)-PET* for neuroendocrine tumors from the National Comprehensive Cancer Network® (NCCN) Guideline for Neuroendocrine and Adrenal Tumors . (log-in required to access) *This service is available at multiple Kaiser Permanente facilities. Please click to view Lutathera criteria
Head and Neck Cancers	1) Staging indicated for: a) Stage III-IV disease of oral cavity, oropharynx, glottic larynx and supraglottic larynx, hypopharynx, ethmoid sinus b) Nasopharynx, Paranasal sinus, and Maxillary sinus: Imaging optional for evaluation of distant metastases (i.e. chest, liver, bone) for stage III-IV disease. Naso-pharyngeal cancer may be appropriate for PET for stage II disease if lymph node positive. 2) Restaging (only for stage III – IV cancers) a) Post-treatment evaluation of cancers of head and neck (minimum 12 weeks after radiation completed). If the study is negative, repeat PET not indicated for surveillance. 3) Lip: No PET is indicated in the absence of advanced stage disease (stage III) 4) Salivary: No PET is indicated; CT & MRI as needed 5) Unknown primary in the head and neck (squamous cell carcinoma, adenocarcinoma, or anaplastic/undifferentiated epithelial tumor on FNA) when no tumor is evident on initial eval: Initial evaluation should consist of a flexible fiberoptic laryngoscopy as well of CT of the neck For thyroid see below.
Lung Cancer – Non-small cell	1) A positive PET scan finding can be caused by infection or inflammation, including absence of lung cancer with localized infection, presence of lung cancer with associated infection, and presence of lung cancer with related inflammation. A false negative PET scan can be caused by a small nodule, low cellular density, or low tumor activity for FDG. Serial PET scans are not recommended to follow response to therapy; conventional imaging is preferred. No need for bone scan if PET scan already done. 2) Initial staging: Indicated for stages I-III A or B when active treatment is planned. Not typically recommended for known stage IV. Documentation must show how results will alter treatment for stage IV treatment 3) Radiation planning in patients with significant atelectasis, IV contrast is contraindicated and when improved targeting is sought. (if meets criteria 1 above) See Solitary Pulmonary Nodule Above

Oncological Diagnosis	Indications
Lung Cancer – Small Cell Recommended clinical trials only	1) Initial staging small cell lung cancer (SCLC) when it has been determined to be of limited-stage (i.e. limited to the ipsilateral hemithorax and regional lymph nodes) after standard staging evaluation AND patient is a potential surgical candidate or for a combined modality approach with radiation and chemotherapy 2) Restaging – not recommended for routine follow-up after initial therapy See Solitary Pulmonary Nodule Above
Hodgkin Disease Lymphoma	1) Initial staging a) Essential during initial work-up 2) Early/interim re-staging a) Prognostic value is seen with a PET after 2-4 cycles of standard dose chemotherapy, if change in treatment is anticipated 3) Restaging a) After completion of chemotherapy to assess treatment response and characterize residual mass at the end of treatment OR b) after radiation completion, typically at 3 months 4) Surveillance is not recommended due to risk of false positives 5) Pet Scan – field determination for radiation therapy planning
Melanoma	1) Stage I & II not for routine staging, only to evaluate specific signs or symptoms (CT, MRI also options) 2) Stage III or IV; recommended for baseline staging and/or to address specific signs and symptoms (CT, MRI also options)
Multiple Myeloma	1) Whole-body imaging low-dose CT (<i>often submitted as CPT 76497</i>) scan is preferred modality for patient initial workup for patients suspected of having MM, or Solitary Plasmacytoma. 2) FDG/PET CT is reserved for situations when initial whole-body low-dose CT or MRI is non diagnostic. 3) Whole-body imaging low dose CT is preferred for all Myeloma follow up.
Non-Hodgkin's Lymphoma	<p><u>Low grade lymphoma:</u> PET scan may be indicated for Stage I & II but not routinely for Stage III and IV unless management would be changed See Lymphoma Grade Table below</p> <p><u>Intermediate & High Grade Lymphoma:</u> PET scan is indicated for restaging after completion of therapy (chemotherapy or radiation); not for surveillance See Lymphoma Grade Table below</p> 1) Diffuse large B-cell lymphoma (intermediate) a) Initial staging is essential b) Restaging i) at completion of treatment (wait 8 weeks minimum) c) Early/interim restaging following 2-4 cycles of chemotherapy is controversial and should be done only if a planned change in management is documented. Biopsy of PET positive sites should be considered 2) AIDS-related B-cell lymphoma a) Initial staging is essential 3) Peripheral T-cell Lymphoma a) Initial staging is essential b) Interim restaging for all ALCL and ALK+ i) Repeat studies for all positive studies c) Restaging i) at completion of treatment ii) Repeat studies for all positive studies 4) Extranodal NK/T-cell lymphoma nasal type a) Initial staging is essential b) Post-radiation therapy the role remains uncertain

Oncological Diagnosis	Indications
	5) Pet Scan – field determination for radiation therapy planning
Occult Primary	1) Not routinely recommended. Documentation must clearly identify the clinical reason for such testing.
Ovarian	1) PET scan not routinely indicated for initial staging 2) Restaging: may be covered if conventional imaging (CT, MRI) give indeterminate results and PET will alter management 3) May be approved if there is a solitary lymph node that is a possible candidate for surgical resection
Prostate	1) Use is unproven and should be provided within a clinical trial setting
Prostate – Axumin PET	Axumin no longer recommended; please see PSMA PET criteria here
Prostate- PSMA PET	Please see PSMA PET criteria here
Soft Tissue Sarcoma	1) Not routinely recommended 2) Baseline staging, for cases when grade is uncertain or when conventional imaging has not conclusively evaluated the possibility of distant metastasis 3) Differentiation of suspected tumor from radiation or surgical fibrosis
Thyroid	1) Localization to plan treatment for papillary or follicular thyroid carcinoma with the following: <ul style="list-style-type: none"> a) Previously treated with thyroidectomy and radioiodine ablation AND b) Thyroid Globulin (TG-antibody) positive (stimulated or on suppression) greater than 10 AND c) Negative structural imaging i.e. ultrasound and CT negative 2) Initial staging OR follow-up for localization to monitor response to prior treatment (surgery, I131, radiation therapy, or tyrosine kinase inhibitor), for treatment planning or to predict prognosis for the following: <ul style="list-style-type: none"> a) Aggressive tumors confirmed by histology (Hurthle cell, poorly differentiated, anaplastic) OR b) Aggressive behavior i.e. any tumor with confirmed metastasis showing progression on structural imaging or by rising TG level despite prior treatment
All other cancers not listed above	1) Evaluated on a case by case basis, in conjunction with consultants and national guidelines

The Indolent Lymphomas**B Cell Neoplasms**

- Small lymphocytic lymphoma/B-cell chronic lymphocytic leukemia
- Lymphoplasmacytic lymphoma
- Plasma cell myeloma/plasmacytoma
- Hairy Cell leukemia
- Follicular lymphoma (grade I and II)
- Marginal zone B-cell lymphoma
- Mantle cell lymphoma

T Cell Neoplasms

- T-cell large granular lymphocyte leukemia (LGL disease)
- Mycosis fungoides
- T-cell prolymphocytic leukemia
- T-cell large granular lymphocyte leukemia

Natural Killer cell neoplasm

- Natural killer cell large granular lymphocyte leukemia

Low Grade

- Malignant lymphoma
Small lymphocytic
consistent with CLL
plasmacytoid
- Malignant Lymphoma, follicular
Predominantly small cleaved cell
- Malignant lymphoma, follicular
Mixed, small cleaved and large cell

The Aggressive Lymphomas**B Cell neoplasms**

- Follicular lymphoma (grade III)
- Diffuse large B-cell lymphoma
- Mantle cell lymphoma

T cell neoplasm

- Peripheral T-cell lymphoma
- Anaplastic large cell lymphoma, T/null cell

Intermediate Grade

- Malignant Lymphoma, follicular
Predominantly large cell
- Malignant lymphoma, diffuse
Small cleaved cell
- Malignant lymphoma, diffuse
Mixed, small and large cell
- Malignant lymphoma, diffuse
Large cell
cleaved cell
non-cleaved cell

The Highly Aggressive Lymphomas**B cell neoplasms**

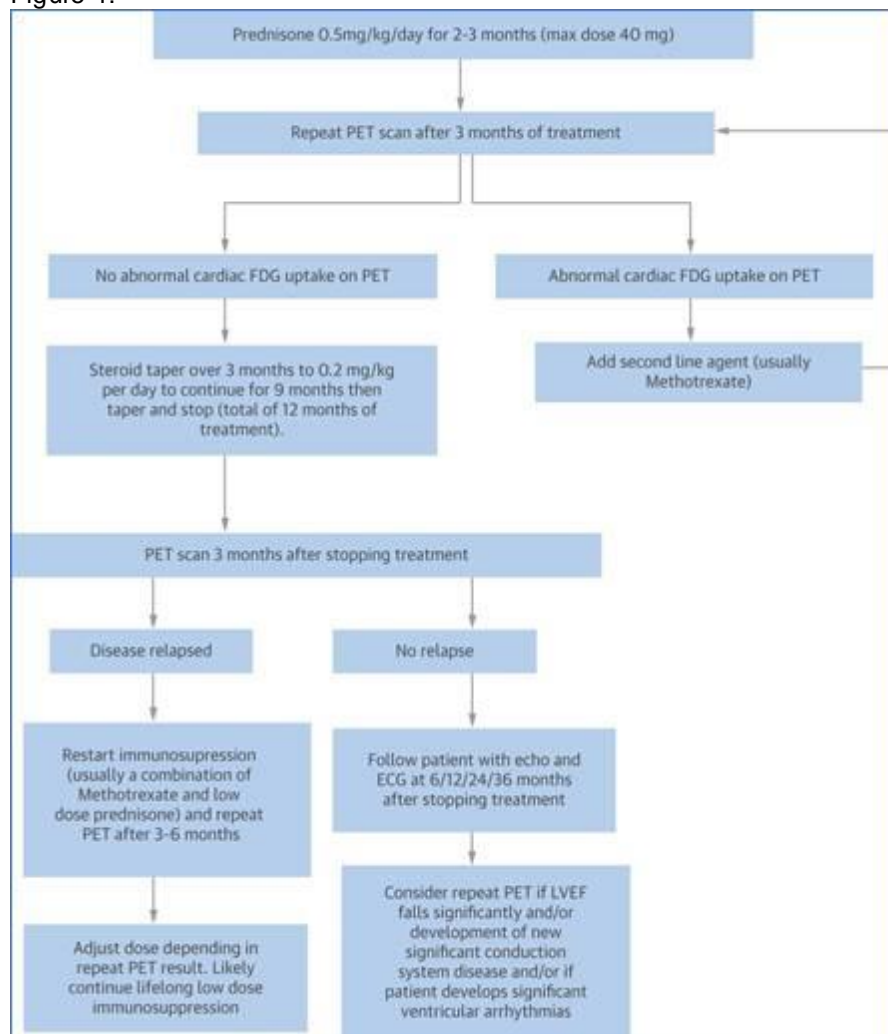
- Burkitt's lymphoma
- Precursor B lymphoblastic leukemia/lymphoma

High Grade

- Malignant Lymphoma
Large cell, immunoblastic
- Malignant lymphoma
Lymphoblastic
- Malignant lymphoma
Small non-cleaved cell
Burkitt's
Non-Burkitt's

Non-oncological conditions	Indications
<p>Heart For myocardial Viability Using Fluorodeoxy-D-glucose (FDG)</p>	<ol style="list-style-type: none"> 1. Determine myocardial viability prior to revascularization for patients who are potential candidates for CABG or stent if alternate diagnostic testing are not suitable or non-diagnostic <ol style="list-style-type: none"> a. SPECT is inconclusive or contraindicated due to BMI greater than 40 AND b. dobutamine stress echocardiogram is inconclusive or contraindicated AND c. cardiac MRI is contraindicated or non-diagnostic 2. Sarcoidosis with suspected/known cardiac involvement <ol style="list-style-type: none"> a. For initial diagnosis to evaluate active cardiac sarcoidosis <ol style="list-style-type: none"> a. if MRI cannot be performed b. if MRI is non-diagnostic or inconclusive, and high clinical suspicion for cardiac sarcoidosis remains c. if MRI is positive for cardiac sarcoidosis, a subsequent PET can be done for assessment of active myocardial inflammation b. Repeat PET study as per the algorithm below (Figure 1: Birnie, D. H., Nery, P. B., Ha, A. C., & Beanlands, R. S. B. (2016, July 26). Cardiac Sarcoidosis. Retrieved March 20, 2020, from http://www.onlinejacc.org/content/68/4/411) <ol style="list-style-type: none"> c. Routine surveillance with PET without a known diagnosis of cardiac sarcoidosis is not medically indicated. Serial evaluation while on

Figure 1:



Non-oncological conditions	Indications
	treatment for cardiac sarcoidosis should not be more frequent than 3 months. If there is a request in a shorter time frame, Kaiser Permanente Medical Director review is required.
Perfusion of the Heart Using Ammonia N-13 or Using Rubidium 82	1) Following inconclusive SPECT prior to revascularization (other diagnostic tests or alternative test are contraindicated or not suitable).
Epilepsy refractory Seizures	1) pre-surgical evaluation of refractory seizures

Other forms of PET Scans	Indications
¹⁸F-florbetapir (Amyvid) PET for Alzheimer's Disease Flortaucipir F 18 injection PET for Alzheimer's Disease FDG Alzheimer's Disease and Dementia C-11 Acetate PET for Diagnosing Primary and Metastatic Prostate Cancer ¹⁸F Fluoro-Estradiol PET (FES-PET) to Measure Estrogen Receptor Expression - Breast Cancer ¹⁸F-NaF PET for the Detection of Bone Metastases Fluorodopa F-18 injection PET for Parkinsonian syndrome	There is insufficient evidence in the published medical literature to show that this service/therapy is as safe as standard services/therapies and/or will provide better long term outcomes than current standard services/therapies.

If requesting these services, please send the following documentation to support medical necessity:

- Last 6 months of clinical notes from requesting provider &/or specialist
- Last 6 months of radiology notes if applicable

[Positron Emission Mammography \(PEM\)](#) (Click here for link)

The following information was used in the development of this document and is provided as background only. It is provided for historical purposes and does not necessarily reflect the most current published literature. When significant new articles are published that impact treatment option, Kaiser Permanente will review as needed. This information is not to be used as coverage criteria. Please only refer to the criteria listed above for coverage determinations.

Background

Positron Emission Tomography has been studied over the past few years at the University of Washington as well as other academic centers. The efficacy of this scan is still being evaluated. Because medical staff members have asked to have this study covered for cancer detection, a criteria set for medical necessity has been developed which involves review by the Medical Director of the radiology department and maintenance of a request log with determination outcomes.

Positron emission tomography (PET) also known as positron emission transverse tomography (PETT), or positron emission coincident imaging (PECI), is a noninvasive imaging procedure that assesses perfusion and the level of metabolic activity in various organ systems of the human body. A positron camera (tomograph) is used to produce cross-sectional tomographic images by detecting radioactivity from a radioactive tracer substance (radiopharmaceutical) that is injected into the patient.

Positron Emission Tomography (PET) is a non-invasive nuclear medicine scanning technique that provides unique diagnostic information that cannot be obtained by other imaging modalities. While CT and MRI provide detailed images of the patient's anatomy; PET scanning reveals vital information concerning cellular function. This functional information can be critical in the evaluation of a variety of common and serious diseases. PET has shown utility in the management of a wide range of malignancies including lung cancer, colon cancer, lymphoma and melanoma. PET scanning also plays an important role in the evaluation of certain neurologic and cardiac diseases and the applications of this unique imaging modality continue to expand.

Recent developments in the field of PET scanning are certain to lead to a rapid expansion in the utilization of this powerful technique. There have been improvements in the resolution of the cameras allowing for higher diagnostic yield. Reimbursement issues are being worked out and HCFA has approved payment for several indications in the area of oncology. Additional indications may be approved in the near future. The problems surrounding the delivery of the radioisotopes are also being solved. This is particularly true for the Puget Sound area where a production facility (cyclotron) has recently been built in Kent.

Several careful studies have shown that there is a cost benefit associated with PET. In many cases PET will reveal findings not identified by CT or MRI, resulting in a more appropriate and timely diagnostic evaluation. Costs for unnecessary procedures are avoided. This results in an overall cost saving, despite the initial cost of performing the PET study.

Interest in PET scanning continues to grow rapidly in both the national and local medical community. Several local hospitals already have PET capability and the number of facilities offering this important diagnostic capability is certain to expand quickly. Many facilities are beginning their PET program by utilizing a mobile service. There are a number of mobile PET companies that are already providing or will soon be providing service to our area. This approach would allow for a minimal initial investment with low risk and could provide the opportunity to provide PET scanning at a number of different GH facilities on a rotating basis. In the future, depending on patient volume, consideration may be given to installing a permanent facility.

Evidence and Source Documents

[Alzheimer's Disease and Dementia](#)

[Breast Cancer, Staging and Re-Staging](#)

[Cervical Cancer, Staging and Re-Staging](#)

[Colorectal Cancer, Staging and Re-Staging](#)

[Esophageal Cancer, Diagnosis, Staging and Re-Staging](#)

[¹⁸F Fluoro-Estradiol to Measure Estrogen Receptor Expression in Advanced Breast Cancer](#)

[Head and Neck Cancer, Diagnosis, Staging and Re-Staging](#)

[Melanoma, Staging and Re-Staging](#)

[Prostate Cancer, C-11 Acetate for Diagnosing Primary and Metastatic](#)

[Refractory Seizures, Pre-Surgical Evaluation](#)

[¹⁸F-NaF PET for the Detection of Bone Metastases](#)

[¹⁸F-florbetapir \(Amyvid\) PET for Alzheimer's disease](#)

[Axumin Injection](#)

Medical Technology Assessment Committee (MTAC)

Alzheimer's Disease and Dementia

BACKGROUND

Dementia is a general decline in multiple cognitive abilities including language, memory, and logical thinking. It is a common disorder in the elderly, and has many potential causes. Alzheimer's disease (AD), a degenerative neurological condition, is the most common form of dementia in the elderly and accounts for approximately two thirds the cases in the USA. Other causes of dementia include vascular dementia, dementia with Lewy bodies, dementia due to Parkinson's disease, frontotemporal dementia and others. These have to be considered in the differential diagnosis and ruled out before a diagnosis of AD is made. Alzheimer's disease is mainly characterized by progressive memory impairment and other cognitive dysfunctions that can interfere with the patient's normal daily activities and social life. Its onset is gradual and involves continuing cognitive decline. The milder forms are classified as "possible" and the more advanced forms as "probable" AD. The standard evaluation of dementia and potential AD is extensive and include medical and psychiatric history, physical examination, neuropsychologic mental status testing, lab tests and structural imaging. MRI and CT scans are used to detect structural changes late in the disease, and in ruling out tumors or other abnormalities in the brain that may cause dementia symptoms. Early and accurate diagnosis of dementia has become of greater concern lately because of the availability of more effective drug therapies to treat the symptoms of the disease. These medications would have a greater impact when used in the earlier stages of the disease (Silverman 1999). The most widely used diagnostic criteria for dementia in North America are based on definitions in the National Institute of Neurological and Communicative Disorders and Stroke-Alzheimer's Disease and related Disorders Association (NINCDS-ADRDA) Work Group. Diagnostic criteria for AD have also been grouped by the American Psychiatric Association in the Diagnostic and Statistical Manual of Mental Disorders (DSM-IV). The clinical evaluation based on these criteria is relatively accurate in ruling out dementia due to causes other than AD, and in identifying probable AD when the level of dementia is moderate to severe. The clinical criteria that define AD are not the ideal gold standard because the clinical diagnosis does not always conform with the pathological diagnosis. The perfect gold standard for the definitive diagnosis of AD or other specific forms of dementia is the histopathological examination of brain tissue, which is very rarely done during the patient's lifetime. Specific histopathologic findings of AD include gliosis, plaques, tangle formation, and neuronal loss (Hoffman 2000). Numerous studies have found that Alzheimer's disease and other neurodegenerative diseases could produce significant alterations in brain metabolism. AD was found to be associated with focal reduction of the cerebral metabolic rate of glucose (CMR-G1c) mainly in the temporoparietal, and frontolateral regions of the brain. Bilateral temporoparietal hypometabolism were found to be the characteristic patterns seen in AD but are not specific to it. Gamma camera imaging and single photon emission computed tomography (SPECT) have been used to measure the cerebral blood flow in the brain. However, they may not be very effective in identifying localized metabolic defects. Positron emission tomography (PET) is another technique proposed as a means for the diagnosis of dementia. PET is a functional nuclear imaging modality that uses biochemical rather than structural information to produce images. It involves using positron-emitting radioisotopes to generate radioactivity. The levels of radioactivity originating from a given point are recorded using certain camera-like devices. Different radiopharmaceuticals can be used in PET imaging. The most commonly used in brain imaging is ^{18}F -fluorodeoxyglucose (FDG) which has the ability to compete with glucose for absorption and metabolism in a variety of cell types, including neurons. In AD and some other forms of dementias the ability of the cells to take up glucose and FDG is impaired. Theoretically, FDG PET may help in the early diagnosis of AD and other forms of dementia by highlighting these regions of decreased FDG uptake before any structural damage can be detected by MRI or CT scans. FDG PET is usually done under resting conditions, but can be also performed under activation conditions to study the extent of neuronal stimulation. Brain PET scans can be interpreted by visual, quantitative and semi quantitative methods. The visual method, the most commonly used, greatly depends on the observer's experience, and lacks a clear cutoff between normal and pathological findings. PET scanners are approved by the Food and Drug Administration (FDA) for general use. The FDA does not approve imaging devices as PET scanners for specific indications. FDG PET is FDA approved for evaluating seizures, and was determined to be safe and effective in detecting malignancy. However, to date no PET radiotracers have been approved by the FDA for evaluating AD or other forms of dementia.

04/09/2003: MTAC REVIEW

Alzheimer's Disease and Dementia

Evidence Conclusion: There is insufficient evidence to allow us to draw conclusions about the value of PET in the diagnosis of AD and non-AD dementias, or in the assessment of treatment response. There was also no evidence on the impact of PET on the disease management and clinical outcome for patients with AD. The review focused on the use of FDG PET in the diagnosis of Alzheimer's disease. It also focused on studies with histopathological confirmation, which provides a definitive diagnosis of AD because many forms of dementia have overlapping clinical presentations. The two studies reviewed had this advantage of histopathologic confirmation, but each had some validity threats that limit generalization of their results. Both studies were conducted among selected groups of patients who do not generally represent those who undergo dementia evaluation. In addition, neither study evaluated the impact of PET scanning on the disease management or the health outcome of the

patients. Among the other limitations of the studies, is the small sample size in Hoffman's study, and the inclusion of two different cohorts with different protocols in Silverman's study. In these studies, Hoffman et al reported that FDG PET scans had a sensitivity of 92.9% and 87.5% in diagnosing AD alone, or with concurrent non AD dementias, and a specificity of only 62.2% and 66.7% respectively. Silverman reported a similar sensitivity of 93.8%, but a higher specificity of 73.2% for patient with neuropathologic confirmation of their AD diagnosis. In conclusion, the available studies do not provide sufficient evidence to support the addition of PET to the standard clinical evaluation of patients with Alzheimer's disease/dementia, and further prospective studies are needed to establish its diagnostic and prognostic values. An ideal study would include a large representative sample of patients, who would be followed up from the development of symptoms until death when histopathologic confirmation can be made. Ideally also the patients would be randomly assigned to different management groups to assess the value of PET scanning on the outcome of the disease.

Articles: *Diagnosis of Alzheimer's disease dementias:* The search revealed 24 studies. All were prospective with the exception of 2 studies. The inclusion/exclusion criteria were not specific in all of the studies, and the blinding of PET interpreters was not always discussed. In 22 of these studies clinical evaluation was the gold standard, and in only 2 studies FDG PET performance was compared to histopathological findings. The use of clinical criteria for the diagnosis of AD does not give an accurate assessment of sensitivity and specificity of PET, and the true accuracy of the test needs histopathologic confirmation. The following two studies with pathological confirmation were selected for critical appraisal: Hoffman JM, Welsh-Bohmer KA, Hanson M, et al. FDG PET in patients with pathologically verified dementia. *J Nucl Med* 2000;41:1920-1928. See [Evidence Table](#). Silverman DH, Small GW, Chang CY, et al. Positron Emission Tomography in Evaluation of Dementia. *JAMA* 2001;286:2120-2127. See [Evidence Table](#). ***Diagnosis of non- Alzheimer's disease dementias:*** The search revealed 7 studies on the diagnosis of vascular dementia, dementia with Lewy bodies, or frontotemporal dementia using FDG PET. All studies had very small sample sizes (7 to 21 patients), and various methodological issues including nonblinding of PET interpreters, nonspecific inclusion/exclusion criteria, and lack of histological confirmation of the diagnosis. None was selected for critical appraisal. ***Assessment of AD treatment response:*** The search revealed 5 studies evaluating the role of FDG PET in assessing the treatment response. All had very small sample sizes (10 to 30 patients), and various methodological issues including nonblinding of PET interpreters, nonspecific inclusion/exclusion criteria, and lack of histological confirmation of the diagnosis. Two of these studies were conducted to evaluate the effect of passive audiovisual stimulation on the cerebral metabolic response, and another to study the effect of a therapeutic agent (propentofylline) in enhancing the metabolic response to auditory memory stimulation. None of these studies was selected for critical appraisal.

The use of FDG PET in the evaluation of Alzheimer's Disease or Dementia does not meet the *Kaiser Permanente Medical Technology Assessment Criteria*.

12/20/2010: MTAC REVIEW Alzheimer's Disease and Dementia

Evidence Conclusion: The first retrospective cohort study included 45 patients with dementia and assessed whether the addition of FDG-PET to clinical history and examination improves accuracy in distinguishing frontotemporal dementia (FTD) and Alzheimer's disease (AD). Findings from this study suggest that the addition of FDG-PET to clinical diagnosis improves diagnostic accuracy, sensitivity, and specificity in distinguishing FTD from AD. However, because of the characteristics of this analysis (results were reviewed by six experts who were aware that the entire population had dementia) the result of this study may not be applicable to clinical practice. Additionally, the effect on disease management and health outcomes cannot be determined from this study (Foster 2007).

	Diagnostic accuracy, sensitivity, and specificity	
	Clinical scenario	Clinical scenario + FDG-PET
	Mean (95% CI)	
Accuracy	78.8% (73-87)	89.2% (87-91)
Alzheimer's disease		
Sensitivity	86% (74-100)	97.6% (94-100)
Specificity	63% (36-79)	73.2% (57-82)

The second retrospective cohort study included 44 patients with and without dementia and evaluated the potential ability of both clinical and imaging diagnoses to detect AD. The results of this study suggest that the addition of FDG-PET to the initial clinical diagnosis of AD increased the sensitivity and specificity of the diagnosis; however, it is unknown whether these results will translate into clinical practice as two reviews rated each PET scan and the diagnosis of AD was determined at a multidisciplinary conference after review of all clinical data. Additionally,

confidence intervals were not reported and there was a delay between initial examination and PET examination. PET imaging was performed an average of 1.3 years after initial examination (Jagust 2007).

Sensitivity and specificity		
	Initial	Initial + PET
Sensitivity	76%	84%
Specificity	58%	74%

Conclusion:

There is insufficient information to determine whether the addition of FDG-PET to clinical diagnosis will lead to a more accurate diagnosis of AD.

Articles: Several articles were identified that evaluated whether the addition of a FDG-PET scan to clinical diagnosis would lead to a more accurate diagnosis of AD. The majority of these studies compared the addition of FDG-PET to a clinical diagnosis, which may be inaccurate and therefore not an ideal gold standard. Two small retrospective cohort studies that compared the addition of FDG-PET to a clinical diagnosis to a postmortem pathologic diagnosis of AD were selected for review. The following studies were critically appraised: Foster NL, Heidebrink JL, Clark CM, et al. FDG-PET improves accuracy in distinguishing frontotemporal dementia and Alzheimer's disease. *Brain* 2007; 130:2616-2635. See [Evidence Table](#). Jagust W, Reed B, Mungas D, et al. What does fluorodeoxyglucose PET imaging add to a clinical diagnosis of dementia? *Neurology* 2007; 69:871-877. See [Evidence Table](#)

The use of FDG PET in the evaluation of Alzheimer's Disease or Dementia does not meet the *Kaiser Permanente Medical Technology Assessment Criteria*.

Breast Cancer: Diagnosis, Staging and Restaging

BACKGROUND

Positron emission tomography (PET) with ¹⁸F-fluorodeoxyglucose (FDG) has the potential for demonstrating tumor metabolic activity before structural changes can be shown by other methods such as computed tomographic (CT) imaging. FDG is a biological tracer that allows the evaluation of glucose metabolism. Tumor cells have increased glucose metabolism compared to benign cells and PET imaging with FDG takes advantage of this metabolic difference. Elevated uptake of FDG has been shown in several types of malignant primary tumors. FDG PET is potentially useful for diagnosis, staging and restaging of breast cancer. **Diagnosis:** While mammography remains the main imaging technique for screening breast lesions, it may be nondiagnostic in women with dense breasts and fibrocystic disease. **Staging:** Detection of tumor-involved lymph nodes is important. If PET can accurately detect axillary node involvement, patients may be able to avoid surgical morbidity from axillary dissection. **Restaging:** Another potential use of PET is to detect metastatic breast cancer outside of the breast and axillary nodal basins. This can help identify patients who are most likely to benefit from chemotherapy or radiation therapy. **Monitoring response to chemotherapy:** The response to chemotherapy could be monitored by PET because FDG uptake may decrease more in tumors that respond to chemotherapy than those that do not respond (Hoh & Schiepers, 1999).

06/07/2001: MTAC REVIEW

Breast Cancer: Diagnosis, Staging and Restaging

Evidence Conclusion: Diagnosis - The one study reviewed, Avril, found that FDG PET was insufficiently sensitive and specific at diagnosing breast tumors. Using the more conservative image interpretation, the negative predictive value was only 61%. This was a reasonably well-done study with a sample size of 144. Staging (staging of axilla) - The three studies had sensitivities varying from 79-90% and specificities varying from 91-97%. FDG PET seemed to perform better than clinical examination. False-negative results do occur with FDG PET. Restaging - The one study reviewed (Moon) suggests that FDG PET may not have sufficiently high sensitivity and specificity to forgo biopsy. This was a reasonably well-done study with n=57 patients. Replication of this study and comparisons with other diagnostic tests would provide stronger evidence about whether or not FDG PET and other non-invasive procedures can be used to restage breast cancer. Monitoring response to chemotherapy - The Smith study, which had a small sample size, found that primary breast cancers that improved clinically had a greater reduction in the rate of FDG uptake after one pulse of chemotherapy than cancers that did not respond to chemotherapy. As the authors conclude, these findings need to be replicated in larger studies with strong methodologies. In addition, more work needs to be done on determining the appropriate amount in decrease of FDG update to indicate a clinical response to chemotherapy.

Articles: The search yielded 120 articles. Articles that were opinion pieces, basic science, dealt with technical aspects of the FDG PET procedure or had very small numbers of patients (i.e. <30) were excluded. Articles on diagnosis, staging and restaging were considered separately. There was one empirical study on the use of FDG PET for initial diagnosis of breast cancer. Four articles were identified on the use of PET for staging of the axilla. One of these did not have well described methodology and results; a summary evidence table was created for the other three articles which were similar methodologically. One article focused on the use of FDG PET for restaging breast cancer (detecting recurrent or metastatic disease). There were two articles that addressed the use of FDG PET for monitoring patients' response to chemotherapy. The study with the stronger methodology was reviewed. Evidence tables were created for: **Diagnosis:** Avril N, Rose M, Schelling J, Dose W, Kuhn S, Weber W. et al. Breast imaging with Positron Emission Tomography and fluorine-18 fluorodeoxyglucose: Use and limitations. J Clin Oncol 2000; 18: 3495-3502. See [Evidence Table](#). **Staging:** Smith IC, Ogston KN, Whitford P, Smith FW, Sharp P, Norton M et al. Staging of the axilla in breast cancer: accurate in vivo assessment using positron emission tomography with 2-(fluorine-18)-fluoro-2-deoxy-d-glucose. Ann Surg 1998; 228: 220-227. See [Evidence Table](#). Avril N, Dose J, Janicke F, Ziegler S, Romer W, Weber W et al. Assessment of axillary lymph node involvement in breast cancer patients with positron emission tomography using radiolabeled 2-(fluorine-18)-fluoro-2-deoxy-D-glucose. J Natl Cancer Inst 1996; 88: 1204-9. See [Evidence Table](#). Crippa F, Agresti R, Seregni E, Greco M, Pascali C, Bogni A et al. Prospective staging of fluorine-18-FDG PET in presurgical staging of the axilla in breast cancer. J Nucl Med 1998; 39: 4-8. See [Evidence Table](#). **Restaging:** Moon DS, Maddahi J, Silverman DHS, Glapsy JA, Phelps ME, Hoh CK. Accuracy of whole-body fluorine-18-FDG PET for the detection of recurrent or metastatic breast carcinoma. J Nucl Med 1998; 39: 431-435. See [Evidence Table](#). **Monitoring response to chemotherapy:** Smith IC, Welch AE, Hutcheon AW, Miller ID, Payne S, Chilcott F et al. Positron emission tomography using 18-F-Fluorodeoxy-D-glucose to predict the pathologic response of breast cancer to primary chemotherapy. J Clin Oncol 2000; 18: 1676-1688. See [Evidence Table](#)

FDG PET for diagnosis, staging and restaging breast cancer did not pass the *Kaiser Permanente Medical Technology Assessment Diagnostic Test Evaluation Criteria*.

Cervical Cancer, Staging and Re-Staging

BACKGROUND

Cervical cancer is the second most frequently diagnosed gynecological malignancy in women worldwide (Chung et al., 2006). An analysis by the Centers for Disease Control and Prevention (Saraiya et al., 2007) identified about 60,000 cases of incident cervical cancer in the United States between 1998 and 2002. Rates were substantially higher among African-American and Hispanic women than other groups. If detected early, there is a high rate of treatment success with initial cervical cancer. However, the prognosis for women with recurrent cervical cancer is poor. There are limited treatment options, and treatment is often of a palliative nature (Dreyer et al., 2005). There is no generally accepted surveillance approach to detect recurrence in women with a history of cervical cancer. 80-90% of patients with recurrence will have signs or symptoms of disease, leading to investigations to confirm the diagnosis. Biopsy is routinely performed in symptomatic patients to confirm diagnosis. CT and MRI scanning, anatomic imaging techniques, are commonly used for cervical cancer imaging. In particular, CT-scan-directed biopsy is believed to be useful for obtaining histological confirmation of recurrence. There are concerns, however, that these techniques may result in false-positives due to the inability to distinguish between tumor masses and masses of necrotic or scar tissue, and false-negatives due to the inability to identify small tumors (Dreyer et al., 2005; Havrilesky et al., 2005). Positron emission tomography (PET) with 18F-fluorodeoxyglucose (FDG) is proposed as an alternative to CT and MRI to confirm cervical cancer recurrence in symptomatic patients. In addition, it is proposed as a method for early detection of cervical cancer recurrence in asymptomatic women. Unlike CT and MRI, PET is a functional imaging method and examines cellular function. PET is commonly used with the biological tracer FDG, a glucose analog, which allows the evaluation of glucose metabolism. This is useful for detecting cancer since FDG is preferentially taken up by and retained within malignant cells. PET has shown utility in the management of a wide range of malignancies including lung cancer, colon cancer, lymphoma and melanoma.

08/04/2007: MTAC REVIEW

Cervical Cancer, Staging and Re-Staging

Evidence Conclusion: Diagnostic accuracy - The best available evidence on diagnostic accuracy of PET for cervical cancer recurrence is from a meta-analysis of observational studies (Havrilesky et al., 2005). To be included in the meta-analysis, diagnostic accuracy studies needed to include a reference standard (histology or clinical follow-up) for all participants. The Havrilesky analysis is limited, however, because all of the available studies were observational, retrospective and with small sample sizes (most had fewer than 40 patients). A pooled analysis of 3 studies in patients with a clinical suspicion of recurrence found a pooled sensitivity for PET of 0.96 (0.87-0.99) and specificity of 0.81 (0.58-0.94). A pooled analysis of 2 studies in patients without a clinical

© 1997 Kaiser Foundation Health Plan of Washington. All Rights Reserved. [Back to Top](#)

suspicion of recurrence found a sensitivity of 0.92 (0.77-0.98) and specificity of 0.74 (0.69-0.90). There is insufficient evidence on the diagnostic accuracy of PET compared to CT or MRI. No studies were identified that compared the accuracy of these tests in women with a clinical suspicion of cervical cancer recurrence. Diagnostic impact - Three small studies addressed the diagnostic impact of PET (The Lai and Belhocine studies were discussed in the Havrilesky meta-analysis). The Lai and Yen studies were both conducted among women with biopsy-documented recurrent cervical cancer. The Belhocine study included women with a clinical suspicion of recurrence as well as a small number of women who were undergoing routine post-treatment surveillance. Lai et al. (2004) reported that 22 out of 40 patients with known cervical cancer recurrence had their treatment changed after PET imaging, 15 changed from curative to palliative care. In the Yen et al. (2005) study, 36 out of 55 patients had their treatment plans modified after PET, 9 had a change in curative therapy and 27 switched to palliative therapy. Belhocine et al. (2002) reported that PET findings "induced a treatment" in 24 of the 25 patients with confirmed recurrence, and that PET was "particularly contributive" to the treatment plans of the 13 patients with an equivocal or false-negative result in the routine protocol. The studies on diagnostic impact were all limited by small sample sizes, particularly for sub-group analysis. Moreover, none of the studies provided detailed descriptions of treatment decisions based on CT or MRI versus treatment decisions based on PET. In addition, in the Yen and Lai studies, PET images were fused with CT/MRI results for patients with positive findings, so decisions were based on the combination imaging, not PET alone. Therapeutic impact - There is insufficient evidence on therapeutic impact. None of the studies reported health outcomes in patients managed by PET to those managed without PET. The Lai study included a historical control group; none of the other studies identified had comparison groups. Compared to historical controls, the 15 patients who had undergone surgery for their initial cervical cancer had a better 2-year survival rate. There was no significant difference in survival in the 25 patients who received radiation for their initial cervical cancer compared to historical controls.

Articles: There was a meta-analysis of observational studies on the use of FDG-PET for managing cervical cancer (Havrilesky et al., 2005). The authors systematically searched the literature through April, 2003. The Havrilesky analysis was critically appraised, as well as two studies included in the meta-analysis that reported on changes in treatment plan after PET scans (Belhocine et al., 2002 and Lai et al., 2004). Two studies published after the Havrilesky meta-analysis were considered for review. One study (Chung et al., 2006) was ultimately excluded because did not systematically select patients for scanning or evaluate the impact of PET findings on therapy. The other study (Yen et al., 2005) examined change in treatment following PET and was critically appraised. The studies that were critically appraised include:
Havrilesky LJ et al. FDG-PET for management of cervical and ovarian cancer. *Gynecol Oncol* 2005; 97: 183-191. See [Evidence Table](#).
Lai G-H, Huang K-G, See L-C et al. Restaging of recurrent cervical carcinoma with dual-phase 18F fluoro-2-deoxy-d-glucose positron emission tomography. *Cancer* 2004; 100: 544-552. See [Evidence Table](#).
Belhocine T, Thille A, Fridman V et al. Contribution of whole-body FDG PET imaging in the management of cervical cancer. *Gynecol Oncol* 2002; 87: 90-97. See [Evidence Table](#).
Yen T-C, See L-C, Change T-C et al. Defining the priority of using FDG-PET for recurrent cervical cancer. *J of Nuclear Med* 2005; 45: 1632-1639. See [Evidence Table](#).

The use of FDG-PET in the diagnosis of cervical cancer does not meet the *Kaiser Permanente Medical Technology Assessment Criteria*.

Colorectal Cancer, Staging and Re-Staging

BACKGROUND

Positron emission tomography (PET) with ¹⁸F-fluorodeoxyglucose (FDG) has the potential for demonstrating tumor metabolic activity before structural changes can be shown by other methods such as computed tomographic (CT) imaging. FDG is a biological tracer that allows the evaluation of glucose metabolism. Tumor cells have increased glucose metabolism compared to benign cells and PET imaging with FDG takes advantage of this metabolic difference. Elevated uptake of FDG has been shown in several types of malignant primary tumors. On March 12, 2000, the FDA published a notice in the Federal Register that expanded approval of FDG for new indications. The use of FDG PET for the diagnosis, staging and restaging of colorectal cancer is one of the newly approved indications. In particular, FDG PET may be potentially useful for distinguishing local recurrences from postoperative scarring, for detecting hepatic and extrahepatic metastases prior to any surgery/therapy and for assessing recurrent colorectal cancer when there are indicators other than rising carcinoembryonic (CEA) levels. For these uses, a high negative predictive value (NPV) (the proportion of people who test negative who actually do not have the disease) is desired.

05/30/2001: MTAC REVIEW

Colorectal Cancer, Staging and Re-Staging

Evidence Conclusion: Diagnosing/ Primary staging: The evidence supporting the effectiveness FDG PET for primary staging of colorectal cancer in the absence of CT testing is weak. The strongest article (Abdel-Nabi et al.)

was limited by the small sample size and the fact that assessors had access to CT information when they reviewed PET scans. Recurrence/Restaging: There is evidence to support the accuracy of FDG PET in identifying colorectal cancer recurrence and metastases. There were two reasonably well done comparison of diagnostic test studies (Staub, Imdahl), more recent than the meta-analysis. Study quality was defined as having a sample size >50 (ideally >100), prospective, blinded evaluation of FDG PET scans and use of an appropriate gold standard. Both studies found that PET performed well and was more accurate than CT. There is evidence from Staub that PET findings influence surgical decision-making (61% of patients in the study). The meta-analysis, which had weak methodology, found that there was a change in management for 29% of patients based on PET findings. However, there is no published evidence on the impact of FDG PET for colorectal cancer on health outcomes (e.g. survival).

Articles: The search yielded 63 articles. Articles on primary staging and diagnosis of colorectal cancer and colorectal cancer recurrence were examined separately. There were two articles. There were 7 empirical studies examining primary staging/diagnosis of colorectal cancer and 17 empirical studies examining staging of colorectal cancer recurrences. Most of the studies were case series on FDG PET findings or a comparison of diagnostic tests and had small sample sizes. There was 1 meta-analysis of colorectal cancer recurrence. The rest of the articles were reviews or opinion pieces, assessed non-clinical outcomes or concerned technical aspects of FDG PET usage. The meta-analysis and the case series studies with the strongest methodology and the largest sample sizes were evaluated in detail. Evidence tables were created for the following articles: Diagnosis/ Primary staging:

Abdel-Nabi H, Doerr RJ, Lamonica DM, Cronin VR, Galantowicz PJ, Carbone GM, Spaulding MB. Staging of primary colorectal carcinomas with fluorine-18 fluorodeoxyglucose whole-body PET: Correlation with histopathologic and CT findings. *Radiology* 1998; 206: 755-760. See [Evidence Table](#). Recurrence/ Restaging: Huebner RH, Park KC, Shephard JE, Schwimmer J, Czernin J, Phelps ME, Gambhir SS. A meta-analysis of the literature for whole-body FDG PET detection of recurrent colorectal cancer. *J Nucl Med* 2000; 41: 1177-1189. See [Evidence Table](#). Recurrence/ Restaging: Huebner RH, Park KC, Shephard JE, Schwimmer J, Czernin J, Phelps ME, Gambhir SS. A meta-analysis of the literature for whole-body FDG PET detection of recurrent colorectal cancer. *J Nucl Med* 2000; 41: 1177-1189. See [Evidence Table](#). Imdahl A, Reinhardt MJ, Nitzsche EU, Mix M, Dingeldey A, Einert A. et al. Impact of 18F-FDG-positron emission tomography for decision making in colorectal cancer recurrences. *Langenbeck's Arch Surg* 2000; 385: 129-134. See [Evidence Table](#). Staub L, Schirrmeyer H, Reske SN, Beger, HG. Is 18F-fluorodeoxyglucose positron emission tomography in recurrent colon cancer a contribution to surgical decision making? *Am J Surg* 2000; 180: 1-5. See [Evidence Table](#).

The use of FDG PET as a diagnostic tool for Colon cancer does not meet the *Kaiser Permanente Medical Technology Assessment Criteria*.

Esophageal Cancer, Diagnosis, Staging and Re-Staging

BACKGROUND

2 fluoro-2-deoxy-D-glucose (FDG) freely enters glycogen pathways; however, it gets trapped in these cycles, and significant intracellular accumulation occurs in cells with active glucose metabolism. Degeneration of this radioactive material can be detected by PET. Malignant tumor cells have increased glucose metabolism compared to benign cells. This increased glycolytic activity can be used to detect early-stage disease before any structural abnormality is evident. It can also help exclude the presence of malignant disease in an anatomically altered structure. Esophageal cancer is associated with unfavorable prognosis, and thus accurate determination of the tumor size, extent of local invasion, lymph node involvement, and distant metastases, provides valuable information for prognosis, assessment, and treatment selection. The standard noninvasive staging modalities are CT of the chest and abdomen for evaluating the local tumor extent, and detecting distant metastases, and endoscopic esophageal ultrasound (EUS) for the evaluation of tumor depth and locoregional LN staging in non-obstructing esophageal cancer. However, these techniques entirely depend on structural characteristics for diagnosis. This may cause limitations in diagnostic specificity (false positive findings in enlarged inflammatory LN) and sensitivity (false negative findings in non-enlarged invaded LN). FDG PET has been reported to accumulate in 92% to 100% of esophageal cancers and is potentially useful for diagnosis, staging, and restaging.

05/30/2001: MTAC REVIEW

Esophageal Cancer, Diagnosis, Staging and Re-Staging

Evidence Conclusion: Apparently, three of these studies, two on staging (Flamen and Lerut) and one on restaging (Flamen) of esophageal cancer were made by the same group, and published in different medical journals. These were reasonably well done studies, yet not without biases. The Luketich study had several threats to its validity. Diagnosing and staging: These studies showed that FDG PET is not an appropriate first line diagnostic procedure in the detection of esophageal cancer. It also did not solve the problem of accurate clinical

staging. There was no relationship between the primary tumor standardized uptake value (SUV) and the depth of the tumor invasion (T classification). FDG PET, could not define the esophageal wall, or paraesophageal tissue, and was not helpful in detecting local invasion by the primary tumor. It over staged when it did not distinguish inflammatory from neoplastic nodes, and under-staged when it could not identify minimally involved nodes, or tumors. It also did not discriminate the primary tumor from peritumoral lymph nodes. However, FDG PET was more sensitive than CT scan in detecting distant nodes and occult organ metastases. It also had a higher specificity than CT and EUS combined, in detecting distant nodal metastases. It was recommended by Flamen et al, in their two studies, that the positive findings on a FDG PET scan must be interpreted cautiously and verified histologically or radiologically, before a patient is considered as having unresectable disease and denied a curative treatment. Restaging: There was only one study found that focussed on the utility of FDG PET for the diagnosis and staging of recurrent esophageal cancer. The Flamen study showed that FDG PET was highly sensitive in staging symptomatic recurrent esophageal cancer. However, its higher sensitivity was statistically insignificant compared to the other conventional diagnostic procedures. Moreover, the false positive uptake at inflammatory lesions offered a major problem. More studies are recommended to study the potential benefit of PET on earlier diagnosis of recurrent disease. Change in patient management: In two of these studies, Luketich (staging) and Flamen (re-staging), patient management was changed in 15% and 11% of cases respectively. The effect of changing the treatment course on the patient survival and quality of life was not studied.

Articles: The search yielded 22 articles. Articles on diagnosis and primary staging of esophageal cancer and cancer recurrence were examined separately. There were six empirical studies on diagnosis and primary staging of esophageal cancer, and only one study on esophageal cancer recurrence. Most of the articles were case series on FDG PET findings or a comparison of diagnostic tests and had small sample sizes. Some were reviews or opinion pieces. There was no meta-analysis done. The studies with the strongest methodology and larger sample sizes were evaluated in detail. Three of the stronger studies, Flamen (J Clin Oncol), Flamen (J Thorac Cardiovasc Surg), and Lerut, were made by the same group. The Luketich study, that had several threats to its validity, was included to add a different view. Evidence tables were created for the following studies:

Staging: Flamen P, Lerut A, Van Cutsem E, De Wever W, Peeters M, et al. Utility of Positron Emission Tomography for the Staging of Patients with Potentially Operable Esophageal Carcinoma. J Clin Oncol 2000; 18:3202-3210. [See Evidence Table](#). Luketich JD, Friedman DM, Wiegel TL, Meehan MA, Et al. Evaluation of Distant Metastases in Esophageal Cancer: 100 Consecutive Positron Emission Tomography Scans. Ann Thorac Surg 1999; 68: 1133-7. [See Evidence Table](#). Lerut T, Flamen P, Ectors N, Van Cutsem E, Peeters M, et al. Histopathologic Validation of Lymph Node Staging with FDG-PET Scan in Cancer of the Esophagus and Gastroesophageal Junction. A Prospective Study Based on Primary Surgery with Extensive Lymphadenectomy. Annals of Surgery 2000; 232(6): 743-752. [See Evidence Table](#). Restaging: Flamen P, Lerut A, Van Cutsem E, Cambier JP, Et al. The Utility of Positron Emission Tomography for the Diagnosis and Staging of Recurrent Esophageal Cancer. J Thorac Cardiovasc Surg 2000; 120: 1085-92. [See Evidence Table](#).

The use of FDG PET As a diagnostic tool for Esophageal Cancer failed criterion 1 of the diagnostic modality evidence criteria for evaluating efficacy of the evidence for re-staging and passed all criteria for diagnosis.

18F Fluoro-Estradiol to Measure Estrogen Receptor Expression in Advanced Breast Cancer

BACKGROUND

Estrogens are involved in the growth and development of both normal and cancerous breast tissues. The activity of estrogens in breast tissue is mediated by ligand-dependent transcription factors called estrogen receptors (ER). ER expression is generally categorized as ER-positive (ER+) and ER-negative (ER-). ER+ means that a significant number of cancer cells have receptors, generally 5-10% of cells. About 70% of invasive breast cancers are ER-positive. Higher ER expression has been found to be associated with an increased likelihood of response to endocrine therapy. (Murphy & Watson, 2006; Linden et al., 2006). Measurement of ER expression by biopsy at the time of primary diagnosis of breast cancer is standard care. However, it may be difficult to accurately measure ER expression in metastatic breast cancer because ER expression can be heterogeneous. That is, cells at one site may be ER+, while other sites may be ER-. In addition, ER expression may change over time. Recurrent breast cancer may have low ER expression even when the original primary tumor is ER+ (Murphy & Watson, 2006; Linden et al., 2006). 18F Fluoro-Estradiol PET (FES-PET) is proposed as an alternative to biopsy to assess ER expression in metastatic breast cancer. FES-PET for advanced breast cancer has not been previously reviewed by MTAC.

12/04/2006: MTAC REVIEW

18F Fluoro-Estradiol to Measure Estrogen Receptor Expression in Advanced Breast Cancer

Evidence Conclusion: The evidence on accuracy of FES-PET for assessing ER expression in breast cancer tumors is insufficient due to the availability of only one small study on this topic. Mortimer et al., (1996) compared biopsy and FES-PET findings in 41 breast cancer patients. Out of 21 patients identified on biopsy to be ER+,
© 1997 Kaiser Foundation Health Plan of Washington. All Rights Reserved. [Back to Top](#)

FES-PET identified 16 (sensitivity=76%). All 20 patients identified on biopsy as ER- were also negative according to FES-PET (specificity=100%). In addition to the limited quantity of evidence, biopsy is an imperfect gold standard so when there is discordance between biopsy and FES-PET findings, it is not possible to conclusively determine which method identified the "true" ER status. There are preliminary data from another small study with 47 patients (Linden et al., 2006). This study found that quantitative but not qualitative analysis of FES-PET significantly predicted response to hormonal therapy among patients with ER+ breast tumors confirmed by immunochemical analysis. The Linden study was not designed to evaluate the diagnostic accuracy of FES-PET. **Articles:** The ideal study would evaluate the ability of FES-PET to identify ER-positive tumors using biopsy as the best available gold standard. One study (Mortimer et al., 1996) was identified that included both FES-PET imaging and biopsy of breast cancer tumors, although the primary purpose of the study was to correlate ER status with response to systemic therapy, not diagnostic accuracy. One other study was identified (Linden et al., 2006) that evaluated the ability of FES-PET to predict response to hormonal therapy in patients with breast cancer; the second study was restricted to patients with tumors already known to be ER-positive. These two studies were critically appraised: Mortimer JE, Dehdashti F, Siegel BA et al. Positron emission tomography with (FDG and FES) in breast cancer: correlation with estrogen receptor status and response to systemic therapy. Clin Cancer Res 1996; 2: 933-939. See [Evidence Table](#). Linden HM, Stekhova SA, Link JM et al. Quantitative fluoroestradiol positron emission tomography imaging predicts response to endocrine treatment in breast cancer. J Clin Oncol 2006; 24: 2793-2799. See [Evidence Table](#).

The use of ¹⁸F Fluoro-Estradiol PET (FES-PET) in the treatment of advanced breast cancer does not meet the *Kaiser Permanente Medical Technology Assessment Criteria*.

Head and Neck Cancer, Diagnosis, Staging and Re-Staging

BACKGROUND

Positron emission tomography (PET) with ¹⁸F-fluorodeoxyglucose (FDG) has the potential for demonstrating tumor metabolic activity before structural changes can be shown by other methods such as computed tomographic (CT) imaging. FDG is a biological tracer that allows the evaluation of glucose metabolism. Tumor cells have increased glucose metabolism compared to benign cells and PET imaging with FDG takes advantage of this metabolic differences. Elevated uptake of FDG has been shown in several types of malignant primary tumors.

With head and neck cancer, FDG PET can be used to identify lymph node involvement to stage newly diagnosed patients. Lymph node status is the principal prognostic factor affecting the survival of head and neck cancer patients. Another possible application of FDG PET in initial staging is identification of unknown sites of primary cancer in patients who present with cervical nodal disease. An unknown primary cancer site occurs for only 1-5% of patients (Chisin & Macapinlac), but this group is presents special challenges in diagnosis and treatment. FDG PET could also be used to identify disease post-treatment residual disease or disease recurrence. Recurrent head and neck cancer is difficult to diagnose with conventional imaging techniques or clinical examination because of the anatomic changes, inflammation and scarring caused by surgery and radiotherapy.

05/30/2001: MTAC REVIEW

Head and Neck Cancer, Diagnosis, Staging and Re-Staging

Evidence Conclusion: Diagnosing and staging (including identifying lymph node metastases): There were two reasonably well-done prospective studies with sample sizes > 50 comparing FDG PET with other diagnostic modalities. Both showed FDG PET to have superior performance (higher sensitivity and specificity). Positive predictive value of FDG PET and CT varied considerably in the two studies. This provides some evidence about the effectiveness of FDG PET, although the variation in estimates across studies is concerning. Neither of the studies specifically discussed the ways in which FDG PET findings affect patient management. Restaging: Studies were not as strong methodologically as those for staging (e.g. had inconsistent use of a "gold standard"). In the Lapela study, FDG PET did not clearly perform better than CT (in one classification system, FDG PET had higher sensitivity and somewhat lower specificity; in the other classification system, FDG PET performed slightly better, statistical difference in performance is unknown). In the Lonneux study, FDG PET clearly performed better than CT plus MRI, but specificity was low. The available evidence does not permit clear conclusions about the effectiveness of FDG PET at detecting recurrence of head and neck cancer.

Articles: The search for the period 1997 through February 2001 yielded 83 articles. Articles that were opinion or discussion pieces or addressed technical aspects of FDG PET were excluded. There were 4 prospective comparisons of diagnostic test studies with sample sizes for diagnosis/staging and 1 for restaging. Evidence tables were created for the two staging articles with n>50 and with the strongest methodologies. An evidence table was created for the prospective restaging article and for a study of restaging where n=44 but that presented data on the impact of FDG PET on patient management. There are evidence tables for the following studies:

Adams S, Baum RP, Stuckensen T, Bitter K, Hor G. Prospective comparison of 18F-FDG PET with conventional imaging modalities (CT, MRI, US) in lymph node staging of head and neck cancer. *Eur J Nucl Med* 1998; 25: 1255-1260. [See Evidence Table](#). Stokkel MPM, ten Broek F-W, Hordijk G-J, Kooke R, van Rijk PP. Preoperative evaluation of patients with primary head and neck cancer using dual-head 18-fluorodeoxyglucose positron emission tomography. *Ann Surg* 2000; 231: 229-234. [See Evidence Table](#). Lapela M, Eigtved A, Jyrkkio S, Grenman R, Kurki T, Lindholm P. et al. Experience in qualitative and quantitative FDG PET in follow-up of patients with suspected recurrence from head and neck cancer. *Eur J Cancer* 2000; 36: 858-67. [See Evidence Table](#). Lonneux M, Lawson G, Ide C, Bausart R, Remacle M, Pauwels S. Positron emission tomography with fluorodeoxyglucose for suspected head and neck tumor recurrence in the symptomatic patient. *Laryngoscope* 2000; 110: 1493-97. [See Evidence Table](#).

The use of FDG PET As a diagnostic tool for head and neck cancers failed criterion 4 of the diagnostic modality evidence criteria for evaluating efficacy of the evidence.

Melanoma, Staging and Re-Staging

BACKGROUND

Positron emission tomography (PET) with ¹⁸F-fluorodeoxyglucose (FDG) has the potential for demonstrating tumor metabolic activity before structural changes can be shown by other methods such as computed tomographic (CT) imaging. FDG is a biological tracer that allows the evaluation of glucose metabolism. Tumor cells have increased glucose metabolism compared to benign cells and PET imaging with FDG takes advantage of this metabolic differences. Elevated uptake of FDG has been shown in several types of malignant primary tumors. A potential benefit of FDG PET for patient outcome is the ability to improve the selection of patients for surgery and other treatments. On March 12, 2000, the FDA published a notice in the Federal Register that expanded approval of FDG for new indications. One new indication was the use of FDG PET for the diagnosis, staging and restaging of melanoma. FDG PET is not covered for regional lymph node evaluation.

05/30/2001: MTAC REVIEW

Melanoma, Staging and Re-Staging

Evidence Conclusion: The evidence concerning the effectiveness of FDG PET for diagnosing, staging and restaging melanoma is inconclusive. The three best studies identified that examined the efficacy of FDG PET (excluding Wagner which looked only at regional lymph node basins) varied in their findings on sensitivity and specificity:

PET (By lesion) Sensitivity Specificity

Schwimmer* 92 87

Tyler (restaging) 87 43

Rinne (staging) 100 94

Rinne (restaging) 92 94

*Unclear whether staging and/or restaging

In particular, Tyler found substantially lower specificity than the other studies. The Tyler study included patients with advanced melanoma (Stage III) whereas the Rinne study had at least some patients with less advanced disease. Possibly, effectiveness varies by stage of disease but this is not clear from the available evidence. Only the Rinne study compared FDG PET results with conventional imaging and found that PET had superior sensitivity and specificity. However, conventional diagnostics may not have been consistently performed. No study directly compared PET and CT. In addition, the Wagner study found that sentinel node biopsy was more effective than PET for regional lymph node metastases. FDG PET may be useful for some aspects of melanoma staging and not others. There is a deficiency of evidence on long-term patient outcome following FDG PET for melanoma and on any possible adverse effects.

Articles: The search yielded 37 articles. Many of the studies included mixed groups of patients (primary and recurrent melanoma). There was one meta-analysis and several case series or cross-sectional analyses of FDG PET. The rest of the articles were reviews or opinion pieces, assessed non-clinical outcomes or concerned technical aspects of FDG PET usage. Evidence tables were created for the meta-analysis (staging vs. restaging unclear) and the three evaluations of FDG PET with the strongest methodologies. These articles are: Restaging: Tyler DS, Onaitis M, Kherani A, Hata A, Nicholson E, Keogan M et al. Positron emission tomography scanning in malignant melanoma. *Cancer* 2000; 89: 1019-25. [See Evidence Table](#). Staging and restaging: Rinne D, Baum RP, Hor G, Kaufmann R. Primary staging and follow-up of high risk melanoma patients with whole-body 18f-fluorodeoxyglucose positron emission tomography. *Cancer* 1998; 82: 1664-71 [See Evidence Table](#). Wagner JD, Schuwecker D, Davidson D, Coleman JJ, Saxman S, Hutchins G, Love C, Hayes JT. Prospective study of fluorodeoxyglucose positron emission tomography imaging of lymph node basins in melanoma patients undergoing sentinel node biopsy. *J Clin Oncol* 1999; 17: 1508-15 [See Evidence Table](#). Staging/restaging not specified: Schwimmer J, Essner R, Patel A, Jahan A, Shephard JE, Park K et al. A review of the literature for

whole-body FDG PET in the management of patients with melanoma. Q J Nucl Med 2000; 44: 153-67 [See Evidence Table](#) .

The use of FDG PET As a diagnostic tool for Melanoma permits conclusions about the accuracy for diagnosing distant metastases. This excluded accuracy for diagnosing local disease and regional lymph node metastases.

Prostate Cancer, C-11 Acetate for Diagnosing Primary and Metastatic

BACKGROUND

Positron emission tomography (PET) with ¹⁸F-fluorodeoxyglucose (FDG) is used to identify tumors by their increased rates of glucose metabolism compared to benign cells. Prostate tumors grow slowly and have lower rates of glucose metabolism than other types of tumors. Thus, FDG PET is less useful for the diagnosis and monitoring of prostate cancers than for other cancers such as colorectal and head and neck cancer. Carbon-11 (C-11) acetate has been proposed as a more promising tracer for prostate tumor cells. C-11 has a short half-life, only about 20 minutes and the application of C-11 acetate PET is limited to sites that have an on-site medical cyclotron for radiotracer production.

02/13/2003: MTAC REVIEW

Prostate Cancer, C-11 Acetate for Diagnosing Primary and Metastatic

Evidence Conclusion: There is insufficient evidence to determine the ability of C-11 acetate PET to accurately diagnose or monitor prostate cancer. Only one study was identified that compared C-11 acetate PET to a gold standard (Kotzerke et al., 2002) and this study had too small a sample size for meaningful statistical analysis.

Articles: The search yielded 11 articles. All of the empirical studies had small sample sizes (fewer than 50 patients). One study (Kotzerke) compared C-11 acetate PET to a gold standard (transrectal ultrasound and biopsy). However, this study had only 31 patients and the authors did not calculate sensitivity and specificity or do any other statistical analysis due to the small number of patients evaluated. This study was not critically appraised because of its small sample size and lack of statistical analysis.

The use of C-11 Acetate PET in the evaluation of Primary and Metastatic Prostate Cancer does not meet the *Kaiser Permanente Medical Technology Assessment Criteria*.

Refractory Seizures, Pre-Surgical Evaluation

BACKGROUND

Positron emission tomography (PET) with ¹⁸F-fluorodeoxyglucose (FDG) has the potential for identifying areas of seizure focus (epileptogenic region). FDG is a biological tracer that allows the evaluation of glucose metabolism and areas of seizure focus have decreased glucose metabolism (hypometabolism). For patients whose seizures are uncontrolled by medication, surgery may eliminate seizures or make them easier to control. Most patients who are surgical candidates have complex partial seizures of temporal lobe origin. The most common surgical procedure performed is an anterior temporal lobectomy which consists of resection of the lateral temporal neocortex and the mesiobasal temporal cortex. Invasive recording techniques are the most accurate way to localize the epileptogenic region but noninvasive tests are preferred. Possible noninvasive tests are surface EEG, MRI, ictal single photon emission computed tomography (SPECT) and FDG PET.

05/30/2001: MTAC REVIEW

Refractory Seizures, Pre-Surgical Evaluation

Evidence Conclusion: The studies evaluating FDG-PET for the presurgical evaluation of seizures tended to be small and have methodological flaws. Studies suggest that FDG-PET may be useful for presurgical evaluation, but larger, better-done studies need to be done.

Articles: The search yielded 101 studies. Articles that were opinion or discussion pieces, addressed technical aspects of FDG PET, only included children or did not address presurgical evaluation of seizures were excluded. Nine case series/evaluation of diagnostic test studies remained. Two were by the same research group. None of the studies had sample sizes > 50. The two studies with the strongest methodology were reviewed. Strong methodology was defined as including as many of the following elements as possible: prospective, relatively large sample size, comparative studies, quantified PET results, blinded interpretation of FDG PET, consecutive patients. Only one study (Theodore) was prospective, quantified PET results and included > 30 patients. Evidence tables were created for: Theodore WH, Sato S, Kufra CV, Gaillard WD, Kelly K. FDG-positron emission tomography and invasive EEG: Seizure focus detection and surgical outcome. *Epilepsia* 1997; 38: 81-86. (The more recent Theodore study). [See Evidence Table](#) . Knowlton RC, Lazer KD, Ende G, Hawkins RA, Wong STC, Matson GB et al. Presurgical multimodality neuroimaging in electroencephalographic lateralized temporal lobe epilepsy. *Ann Neurol* 1997; 42: 829-37. [See Evidence Table](#) .

The use of FDG PET As a diagnostic tool for Refractory Seizures failed criterion 2 of the diagnostic modality evidence criteria for evaluating efficacy of the evidence for pre-surgical evaluation.

18 F-NaF PET for the Detection of Bone Metastases

BACKGROUND

Bone metastases occur in 50% of oncologic patients, and in up to 70% of patients with breast and prostate cancer. These may result in significant morbidity including pain, pathological fractures, spinal cord compression, bone marrow suppression, and hypercalcemia. In the initial phase, metastatic lesions in the bone infiltrate the bone marrow disturbing the balance and enhancing osteolytic or osteoblastic processes. Fast-developing and aggressive metastases are usually lytic while the slow developing lesions are typically accompanied by osteoblastic processes. Prostate cancer predominantly demonstrates osteoblastic metastases, lung cancer predominantly demonstrates osteolytic metastases, and breast cancer often demonstrates osteolytic or mixed osteolytic and osteoblastic metastases (Cook 2010, Qu 2011, Tarnawska-Pierscinska 2011). Evaluation of metastatic bone lesions is crucial for determining the therapeutic plan and improving patient prognosis. Radionuclide whole-body bone scintigraphy (BS) using technetium-99m-labelled radiopharmaceuticals, such as methylene diphosphonate (99mTc MDP) tracers has been the standard modality used for the evaluation of skeletal malignancy for decades. It is widely available and has the ability of evaluating the entire skeleton within a reasonable amount of time, and at a relatively low cost. BS provides information on the presence, location, extent, and response to therapy of bone metastases. However, it identifies an increased turnover state associated with osteoblastic activity rather than proliferation of tumor cells, and therefore may be less sensitive in detecting early metastases, metastatic tumors that are small in size or confined to the bone marrow, osteolytic lesions, or lesions with minimal or no osteoblastic activity. Lytic lesions are visible by scintigraphy studies as “cold” areas that are difficult to interpret. BS may also lead to false positive findings in cases of osteoarthritis, healing fractures, and inflammation (Yen 2010, Cheng 2011, Chang 2012, Tarnawska-Pierscinska 2011). More recent improvements and developments of other non-invasive methods are increasingly being used for detecting bone metastases. These include multidetector computed tomography (CT), magnetic resonance imaging (MRI), SPECT/CT, and positron emission tomography (PET) with or without computed tomography (PET/CT). Each modality has its advantages and limitations, as well as imaging capability which could be morphologic, functional, or a combination of both. MRI and CT are anatomic imaging modalities that analyze tumor tissue based on their morphologic appearance; while 99mTc MDP bone scintigraphy and PET are functional imaging modalities. Bone scintigraphy identifies bone metastasis by detecting the osteoblastic response to bone destruction by tumor cells and the accompanying increase in blood flow. 18F-FDG PET identifies viable tumors based on the higher glycolytic rates in the neoplasm than in normal tissue, and 18F-labeled sodium fluoride (18 F-NaF), a radiotracer used with PET bone scans, has a skeletal uptake mechanism similar to that of 99mTc, but clears from circulation faster as it does not bind to plasma proteins. 18 F-NaF relies on the exchange of hydroxyl ions in the in the hydroxyapatite crystal and is an indicator of bone metabolic activity. The increased uptake of the tracer in malignant bone lesions reflects the increase in regional blood flow and bone turnover characterizing these lesions. 18 F-NaF PET scans may identify lytic bone metastases that may not be detected by 99mTc scintigraphy. The accumulation of fluoride however, is not tumor specific and it may be difficult to differentiate metastases from benign bone lesions such as degenerative diseases (Hetzl 2003, Evan-Sapir 2006, Cook 2010, Liu 2011, Tarnawska-Pierscinska 2012). 18 F-NaF, introduced in the early 1960s, was the first radiopharmaceutical agent used for imaging bone lesions. It was initially used as a planar scintigraphy tracer and has the advantage of high and rapid bone uptake and very rapid blood clearance. It was abandoned however, with the introduction of 99mTc in the 1970s, because the relatively high energy of the annihilation photons produced by the decay of 18F required the use of special scanners. More recently, 18 F-NaF for bone imaging re-emerged with the introduction of PET and the availability of electronic generators that may allow its use. The interest in 18 F-NaF was also increased due to the worldwide shortages of 99mTc-MDP (Grant 2008, Chua 2009, Cook 2009, Yen 2010).

18 F-NaF was cleared by the Food and Drug Administration (FDA) for clinical use in 1972. The approval was then withdrawn, and it is unclear whether it was re-approved.

10/15/2012: MTAC REVIEW

18 F-NaF PET for the Detection of Bone Metastases

Evidence Conclusion: There is limited published evidence on the use of ¹⁸F-NaF PET for the detection of bone metastases. The majority of published studies were on the use of ¹⁸F-FDG PET and ¹⁸F-FDG PET/CT. The studies that evaluated ¹⁸F-NaF PET were small in size, more than half were retrospective in design, and the specific diagnosis was not reported in some and was a variety of carcinomas in others. ¹⁸F-NaF PET with or without CT was mainly compared with bone scintigraphy or FDG PET. No direct comparisons were made vs. MRI. In addition histopathological confirmation as a gold standard was performed in a small number of these studies and not for all participants in the studies. Tateishi and colleagues' meta-analysis as well as Lagaru et al's study

© 1997 Kaiser Foundation Health Plan of Washington. All Rights Reserved. [Back to Top](#)

show that ^{18}F -NaF PET or ^{18}F -NaF PET/CT, may be more sensitive, but with similar specificity to bone scintigraphy and ^{18}F -FDG PET in the detection of bone metastases. Patients included in the studies had a variety of carcinomas which may affect the accuracy of the imaging modalities used. Safety and effect of the using ^{18}F -NaF PET on patient management were not evaluated. The results of the published studies to date should be interpreted with caution. Larger prospective studies among cohorts of patients with specific malignancies are needed to determine whether ^{18}F -NaF PET is safe, improves the detection rate of bone metastases, and has a positive impact on patient management. A randomized prospective multicenter study of almost 500 patients is conducted by the Academy of Molecular Imaging (AMI) is underway in the US to compare ^{18}F -NaF PET with $^{99\text{m}}\text{Tc}$.

Articles: There literature search revealed one meta-analysis and a limited number of small studies that evaluated ^{18}F -NaF PET and compared its performance to one or more other diagnostic modalities used for the detection of bone metastases in patients with lung cancer, breast cancer, prostate cancer, and/or hepatocellular carcinoma. The meta-analysis and a more recent study with generally valid methodology were selected for critical appraisal. Tateishi U, Morita S, Taquri M, et al. A meta-analysis of ^{18}F -Fluoride positron emission tomography for assessment of metastatic bone tumor. *Ann Nucl Med* 2010;24:523-531. See [Evidence Table](#). Lagaru A, Mittra E, Dick DW, et al. Prospective evaluation of $^{99\text{m}}\text{Tc}$ MDP scintigraphy, ^{18}F NaF PET/CT, and ^{18}F FDG PET/CT for detection of skeletal metastases. *Mol Imaging Biol*. 2012;14:252-259. See [Evidence Table](#).

The use of ^{18}F -FDG PET and ^{18}F -FDG PET/CT for bone metastases does not meet the *Kaiser Permanente Medical Technology Assessment Criteria*.

Axumin Injection for PET Scans

BACKGROUND

Prostate cancer is the second most frequently diagnosed cancer across the globe (Wolff et al., 2015). A 2008-2010 data estimated that 15% of men in the United States will be diagnosed with prostate cancer at some point in their lives (Wolff et al., 2015). However, the mortality rate is low because it is a slow growing cancer.

Treatment is based on a number of factors including tumor stage, prostate specific antigen (PSA) value, Gleason score (GS), patient's age, concomitant diseases, life expectancy and patient's preference (Warmuth, Johansson, & Mad, 2010). A wide range of options are available for prostate cancer and these include active surveillance, watchful waiting, radical prostatectomy, hormone therapy, radiotherapy, external beam radiotherapy (EBRT), brachytherapy and chemotherapy (Wolff et al., 2015).

Important proportion (20 to 50%) of men treated for prostate cancer will experience recurrence (Bruce, Lang, McNeel, & Liu, 2012; Roehl, Han, Ramos, Antenor, & Catalona, 2004; Simmons, Stephenson, & Klein, 2007). Of those with recurrent prostate cancer, a high proportion (25%) will develop metastatic disease with morbidity and mortality (Boorjian et al., 2011; James et al., 2015). Given the impact of recurrence, and for better treatment, it is crucial to determine the sites of the recurrence. Diagnostic tests include MRI, bone scintigraphy, CT. However, the accuracy of these standard imaging tests is low (diagnostic yield of 11%) (Choueiri, Dreicer, Paciorek, Carroll, & Konety, 2008). Therefore, tests with better diagnostic yield are necessary. Positron emission tomography (PET) with fluciclovine radiotracer has been the center of attention.

PET is a molecular imaging technique using tumor biology to improve detection of prostate cancer (Parent & Schuster, 2018). PET with tracers visualize receptor profile of tumor cells. Axumin or fluciclovine or Anti-1-amino-3- ^{18}F -fluorocyclobutane-1-carboxylic acid (^{18}F -fluciclovine) is an amino acid PET radiotracer. The characteristics of the tumor-imaging of this radiotracer is similar to the increased amino acid transport found in prostate cancer (Parent & Schuster, 2018). It visualizes the increased amino acid transport associated with tumor cells compared to normal tissues.

One of the benefits of Axumin PET/CT is helping to select optimal treatment strategy (i.e., salvage surgery vs. XRT vs. systemic therapy, depending on site(s)/extent of disease involvement). This can help with resource utilization and patient morbidity: e.g., bypassing futile surgery or local XRT if PET (which is generally more sensitive) identifies more extensive and/or distant disease than CT/MR identify; alternatively, using focal XRT or SABR and avoiding systemic therapy if only isolated or oligometastatic disease.

01/14/2019: MTAC REVIEW

Evidence Conclusion:

Low evidence demonstrates that:

- o The clinical performance of PET with fluciclovine tracer is high in men with suspicion of prostate cancer recurrence after having treatment

- o Compared to standard imaging and other radiotracers (111In-capromab, 11 C-choline, and contrast-enhanced CT alone), the diagnostic performance of PET with fluciclovine is high
- o PET with fluciclovine tracer is clinically useful in defining target volume, and changing management plan
- o No acute toxicity was reported. Longer term studies are warranted

Articles:

PubMed was searched through September 4, 2018 with the search terms (Axumin OR fluciclovine) AND PET AND prostate cancer. The search was limited to English language publications and human populations. The reference lists of relevant studies were reviewed to identify additional publications. The search yielded several articles but six met the inclusion criteria and framework. The articles can be found in evidence tables 1 & 2. [See Evidence Table.](#)

The use of Axumin Injection for PET Scan does not meet the Kaiser Permanente *Medical Technology Assessment Criteria*.

18 F-florbetapir (Amyvid) PET for Alzheimer's disease

BACKGROUND

Alzheimer's disease (AD) is the most common cause of dementia in the elderly people. It is an age-dependent neurodegenerative disease characterized by progressive cognitive impairment, behavior disturbance, and irreversible memory loss. It is estimated that approximately 5 million people aged 65 years or older in the US are diagnosed with AD. The number continues to increase and is estimated to reach 6.7 million by 2025. The etiology of AD has not been established and there is no proven treatment to prevent or slow the progression the disease. It is however, necessary to examine the accuracy of the currently used diagnostic methods as these are critically important for AD research and prevention and treatment studies. Traditionally diagnosis of dementia in North America is based on clinical criteria defined by the National Institute of Neurological and Communicative Disorders and Stroke and Alzheimer's disease and related Disorders Association (NINCDS-ADRDA) Work Group in 1984. In 2011, the National Institute of aging (NIA) and the Alzheimer's Association recommended broadening and refining the 1984 criteria by proposing some changes in the classification criteria of AD, and incorporating biomarkers into the AD criteria. By most diagnostic criteria currently in use, AD is a diagnosis of exclusion based on evidence of chronic progressive cognitive and functional decline of insidious onset in middle aged and elderly patients with no other identifiable alternative explanation such as major, stroke, brain tumor, or systemic disease. Definitive diagnosis of AD depends on the histological examination of brain tissue, which is contraindicated for AD during the patient's lifetime due to the high risk/benefit ratio. While the clinical criteria for diagnosing AD have not changed substantially since they were introduced in 1984, the neuropathological diagnostic criteria have been changed several times in the past three decades. A recent analysis of clinical and neurologic data collected by the National Alzheimer's Coordinating Center from 2005-2010, showed that the sensitivity for AD diagnosis ranged from 70.9-87.3% and the specificity ranged from 44.3-70.8% depending on clinical criteria used. It was also found that as many as 20% of patients diagnosed with AD do not have AD pathology at autopsy (Jack 2011, Beach 2012, Kingwell 2012, Grundman 2013, Newberg 2012). The pathological process of AD is still unclear, but the most widely accepted theory is the amyloid cascade hypothesis, which explains that the accumulation and aggregation of amyloid- β protein in the brain triggers a pathologic cascade ultimately leading to neuronal degeneration and dementia. Autopsy studies showing extracellular accumulation of amyloid plaques and intracellular neurofibrillary tangles support this hypothesis. On the other hand, some investigators postulate that the amyloid- β aggregates are protective, and that the soluble oligomers and not the aggregates are toxic. Another argument against the amyloid- β theory is the failure of a drug that reduces the amyloid- β from the brain to improve cognition in patients with AD. Despite the disagreement about the role that the amyloid- β protein plays in AD, the currently accepted pathologic definitions of AD require the presence of abnormal levels of amyloid- β deposits throughout the cerebral cortex of the patient. Some argue that fibrillary plaques containing amyloid- β may be necessary but insufficient for the diagnosis of AD. Amyloid plaques are also seen in other diseases such dementia with Lewy bodies, vascular dementia, and spongiform encephalopathy. They can also be detected in cognitively normal older adults, and according to researchers, individuals' brains may differ in their ability to tolerate amyloid aggregates based on genetic factors, lifestyle choices, environmental factors, and neuropathological comorbidities, all of which may alter the threshold for the onset of cognitive impairment associated with β -amyloid aggregation (Okamura 2010, Clark 2011, Lister-James 2011, Herholz 2012, Newberg 2012). Lately, *in vivo* amyloid imaging techniques have received a lot of attention for their potential pre-symptomatic detection of amyloid- β pathology. It is believed that *In vivo* imaging agents that are specific and sensitive for detecting amyloid plaques would be very useful for the molecular diagnosis of AD. Investigators suggest that a test which can rule out the presence of pathologically significant levels of amyloid- β plaque in the brain, can rule out a diagnosis of AD even in patients with signs and symptoms consistent with the common forms of dementia. In contrast, the test that indicates abnormal levels of amyloid- β in the brain, may add confidence to the clinical diagnosis of AD, but does not provide a definite diagnosis of AD. On this basis, a number of β -sheet-

© 1997 Kaiser Foundation Health Plan of Washington. All Rights Reserved. [Back to Top](#)

biding radiotracers have been developed for PET. The most widely used agent is the ^{11}C -labeled Pittsburgh compound B (^{11}C -PIB). However, the short half-life (20 minutes) of the radioisotope ^{11}C limits the utility of the compound in the clinical setting as a tool for diagnosis and therapeutic evaluation of AD (Okamura 2010, Wong 2010, Lister-James 2011, Newberg 2012). More recently Avid Radiopharmaceuticals have developed an ^{18}F -labeled amyloid- β PET tracer for the potential detection of AD. The ^{18}F -florbetapir is an amyloid- β avid imaging agent selected from four styryl-pyridine derivatives due to its high affinity and specific binding for amyloid, fast uptake, and fast washout kinetics in the brain. ^{18}F -florbetapir is a radioactive agent with a half-life of 110 minutes that is given before positron emission tomography (PET) imaging of the brain. According to the manufacturer, ^{18}F -florbetapir crosses the blood brain barrier and binds to amyloid aggregates in the brain. A PET scanner can detect the signal emitted by the drug's radioactive fluorine and the resultant image will show the density of amyloid- β neuritic plaques in the brain. The PET-tracer ^{18}F -florbetapir does not measure tau proteins (proteins that stabilize microtubules), which some experts believe plays a crucial role in AD (Okamura 2010, Wong 2010, Lister-James 2011, Newberg 2012, Rosenberg 2013). The PET-tracer ^{18}F -florbetapir (Amyvid, [Avid Radiopharmaceuticals, a subsidiary of Eli Lilly & Co), received FDA approval in 2012 for imaging of the brain in subjects under evaluation for AD and other cases of cognitive impairment. The FDA approval announcement indicated that Amyvid is not a test for predicting the development of AD-associated dementia and is not for monitoring patient response to AD therapy, nor does it replace other diagnostic tests used for the evaluation of cognitive impairment. The labeling explicitly states that a positive scan does not establish a diagnosis of AD or other cognitive disorder.

10/21/2013: MTAC REVIEW

18 F-florbetapir (Amyvid) PET for Alzheimer's disease

Evidence Conclusion: Analytic validity: Clark and colleagues (2011, 2012), evaluated the accuracy of the ^{18}F -florbetapir-PET scans among terminally ill patients who consented to undergo a postmortem biopsy. The mean age of the participants was 79.3 years, 48.6% had AD as their diagnosis, 8.6% had mild cognitive impairment, 17% had another dementing disorder, and 25.7% were cognitively normal. In the initial study (Clark et al, 2011) participants were followed-up until 35 individuals had died and underwent postmortem brain biopsy. Surviving individuals were followed for an additional 1 year after initial study or for up to 2 years after the florbetapir PET scan (Clark et al, 2012). The premortem scan was then compared to the postmortem brain autopsy findings. Each scan was interpreted with at least three nuclear medicine physicians who had undergone training on reading the florbetapir-PET scans. The results of the study showed a mean (among readers) sensitivity of florbetapir-PET scan of 87% and mean specificity of 95% with an overall mean accuracy of 90%. The authors performed a florbetapir-PET scan on a group of 74 healthy young individuals (mean age 26.7 years) to evaluate the specificity of the test. They assumed, and interpreted a negative scan in these patients as amyloid negative without comparing it to the gold standard. The study had the advantage of comparing ^{18}F -florbetapir-PET findings with the gold standard of histopathological findings. However, it also had a number of limitations, many of which were acknowledged by the investigators. These include but are not limited to: The accuracy of Florbetapir-PET was assessed in a nonrandom sample of terminally ill patients who were generally older and/or with poorer health conditions than those in the population that would typically be evaluated for AD in clinical practice. Mean time interval from onset of symptoms of AD (among patients with the disorder) to enrollment was 9 years. This makes it hard to determine how early in the disease course, the amyloid plaques can be detected. Relatively small number of patients underwent postmortem brain biopsies. 22% of the autopsies were performed more than 12 months after the scan: according to the authors, "The relation between post-mortem pathological changes and actual changes in the brain at the time of PET scan might decrease with increasing scan-to autopsy interval (majority reading sensitivity of scan was 96% when autopsy was performed within 1 year from scan and 92% for that performed within 2 years). Both the imaging and histopathological results were distributed bimodally i.e. amyloid positive (moderate to frequent plaques) or negative (no or sparse plaques). There was no intermediate category (sparse to moderate). It is hard to determine whether measurable, but low levels of amyloid at pathology that are not associated with amyloid positive scan represent an early stage of the disease, variant of amyloid deposition, or normal aging. Each scan was interpreted with 3-5 nuclear medicine physicians who had undergone extensive training on reading the scan, which would not be the case outside of an investigational setting. There were variations between the readers interpreting the scan especially with borderline amyloid levels leading to more false negative results. It is worth noting that the study was sponsored by Avid Radiopharmaceuticals, the developer of Amyvid, which was also involved in the collection, analysis, and interpretation of the data, as well as writing the report. Clinical validity - There is weak, insufficient published evidence to determine the usefulness of florbetapir-PET imaging in identifying individuals with mild cognitive impairment or cognitive symptoms who would progress to AD. Doraiswamy and colleagues (2012) investigated whether ^{18}F -florbetapir-PET scan can predict subsequent cognitive decline in older at-risk subjects. The study included 69 cognitively normal individuals at baseline, 51 with mild cognitive impairment (MCI), and 31 patients with AD. All underwent ^{18}F -florbetapir-PET scanning at baseline, and the images were interpreted by three readers as amyloid- β ($\text{A}\beta$) positive or $\text{A}\beta$

negative. The participants were followed-up for 18 months after which they were re-assessed for their cognitive status and function. The results showed that MCI patients who were amyloid positive had significantly greater decline in the majority of psychomotor tests vs. those who were amyloid negative. There was a small yet significantly higher conversion rate from MCI to AD among those who were amyloid positive versus amyloid negative patients. These results have to be interpreted with caution due to limitations of the study. It was relatively small, conducted in an investigational setting, had only 18 months of follow-up, the authors did not adjust for multiple comparisons, and the images were interpreted with three readers with some disagreement.

Clinical utility - Grundman and colleagues (2013) conducted a study to determine the impact of amyloid imaging with ¹⁸F-florbetapir PET on the physicians' diagnostic thinking and intended management of 229 patients with progressive cognitive decline undergoing evaluation for suspected AD and diagnostic uncertainty. The treating physicians provided a provisional diagnosis, an estimate of their diagnostic confidence, and their plan for diagnostic evaluation and management both before and after receiving the results from amyloid imaging with ¹⁸F-florbetapir. The scan was amyloid positive in 133 patients and amyloid negative for 116 patients. No histopathological confirmations were done. The results of the analysis shows that after receiving the results of the florbetapir scan, diagnosis changed in 125/229 (54.6%) patients. Intended medication management of AD increased by 17.7% for patients with positive scans and decreased by 23.3% among those with negative scans. Among subjects who had not yet undergone a completed work up, planned brain structural imaging decreased by 24.4% and planned neuropsychological testing decreased by 32.8%. The analysis also showed that 55% of the subjects were classified with an indeterminate diagnosis after a negative scan rather than a non-AD diagnosis which may reflect lack of confidence in the scan results. The study had the advantage of investigating the clinical utility of ¹⁸F-florbetapir PET scan. However, the physicians were asked whether they would change their management plan, rather than observing the actual patient management over time. The study included patients with progressive cognitive decline and diagnostic uncertainty, and was conducted in a clinical trial setting by memory disorder experts experienced in the diagnosis and treatment of AD, and the scans were over-read by expert nuclear medicine specialists, thus the results may not be generalizable to the overall population evaluated for cognitive complaints. The effect of ¹⁸F-florbetapir PET scan on patient outcome has not been examined and to date, there is no proven therapy for Alzheimer's disease or for lowering and/or reversing amyloid aggregates.

Safety - The most common adverse reactions reported in these published clinical trials include headache (1.8%), musculoskeletal pain (0.8%), fatigue (0.6%), nausea (0.6%), anxiety (0.4%), back pain (0.4%), increased blood pressure (0.4%), claustrophobia (0.4%), feeling cold (0.4%), insomnia (0.4%), and neck pain (0.4%). In conclusion, there is insufficient evidence to determine whether the use of ¹⁸F-florbetapir-PET can accurately predict the risk of AD, would have impact on patient management, or improve net health outcomes of patients at risk of AD. More prospective studies are needed to verify its accuracy and role in the diagnosis and management of the AD. Alzheimer's Disease Neuroimaging initiative 2 (ADNI2) is an ongoing large longitudinal multicenter study that may determine the relationships among clinical, imaging, genetic, and biochemical biomarker characteristics of the entire spectrum of Alzheimer's Disease (AD), as the pathology evolves from normal aging through very mild symptoms, to mild cognitive impairment (MCI).

Articles: The literature search revealed a large number of articles on amyloid- β imaging with PET, but only a limited number of studies was related to the current review. There was one phase III trial and a small number of phases I and II studies on the use of ¹⁸F-florbetapir-PET in patients with mild cognitive impairment (MCI) or dementia due Alzheimer's disease. The search also identified one study on the prognostic utility of the scan, and another on the potential impact of the imaging on patient management. The phase III study (submitted to the FDA), the study on the prognostic utility the imaging, as well as the larger study on its impact on patient management were selected for critical review. Doraiswamy PM, Sperling RA, Coleman RE, et al. Amyloid- β assessed by florbetapir F 18 PET and 18-month cognitive decline: a multicenter study. *Neurology*.2012;79:1636-1644. [See Evidence Table](#). Clark CM, Schneider JA, Bedell BJ, et al for the AV45-A07 Study Group. Use of florbetapir-PET for imaging beta-amyloid pathology. *JAMA*. 2011;305:275-283. [See Evidence Table](#). Clark CM, Pontecorvo MJ, Beach TG, et al for the AV-45-A16 Study Group. Cerebral PET with florbetapir compared with neuropathology at autopsy for detection of neuritic amyloid- β plaques: a prospective cohort study. *Lancet Neurol*. 2012;11:669-678. Grundman M, Pontecorvo MJ, Salloway SP, et al for the 45-A17 Study Group. Potential impact of amyloid imaging on diagnosis and intended management in patients with progressive cognitive decline. *Alzheimer Dis Assoc Disord*. 2013;27:4-15. [See Evidence Table](#).

The use of ¹⁸F-florbetapir (Amyvid) PET for Alzheimer's disease does not meet the Kaiser Permanente *Medical Technology Assessment Criteria*.

Applicable Codes

Considered Medically Necessary when criteria in the applicable policy statements listed above are met:

CPT® Codes	Description
78811	Positron emission tomography (PET) imaging; limited area (eg, chest, head/neck)
78812	Positron emission tomography (PET) imaging; skull base to mid-thigh
78813	Positron emission tomography (PET) imaging; whole body
78814	Positron emission tomography (PET) with concurrently acquired computed tomography (CT) for attenuation correction and anatomical localization imaging; limited area (eg, chest, head/neck)
78815	Positron emission tomography (PET) with concurrently acquired computed tomography (CT) for attenuation correction and anatomical localization imaging; skull base to mid-thigh
78816	Positron emission tomography (PET) with concurrently acquired computed tomography (CT) for attenuation correction and anatomical localization imaging; whole body
78608	Brain imaging, positron emission tomography (PET); metabolic evaluation
78609	Brain imaging, positron emission tomography (PET); perfusion evaluation
78429	Myocardial imaging, positron emission tomography (PET), metabolic evaluation study (including ventricular wall motion[s] and/or ejection fraction[s], when performed), single study; with concurrently acquired computed tomography transmission scan
78459	Myocardial imaging, positron emission tomography (PET), metabolic evaluation study (including ventricular wall motion[s] and/or ejection fraction[s], when performed), single study;
78430	Myocardial imaging, positron emission tomography (PET), perfusion study (including ventricular wall motion[s] and/or ejection fraction[s], when performed); single study, at rest or stress (exercise or pharmacologic), with concurrently acquired computed tomography transmission scan
78491	Myocardial imaging, positron emission tomography (PET), perfusion study (including ventricular wall motion[s] and/or ejection fraction[s], when performed); single study, at rest or stress (exercise or pharmacologic)
78492	Myocardial imaging, positron emission tomography (PET), perfusion study (including ventricular wall motion[s] and/or ejection fraction[s], when performed); multiple studies at rest and stress (exercise or pharmacologic)
78431	Myocardial imaging, positron emission tomography (PET), perfusion study (including ventricular wall motion[s] and/or ejection fraction[s], when performed); multiple studies at rest and stress (exercise or pharmacologic), with concurrently acquired computed tomography transmission scan
78432	Myocardial imaging, positron emission tomography (PET), combined perfusion with metabolic evaluation study (including ventricular wall motion[s] and/or ejection fraction[s], when performed), dual radiotracer (eg, myocardial viability);
78433	Myocardial imaging, positron emission tomography (PET), combined perfusion with metabolic evaluation study (including ventricular wall motion[s] and/or ejection fraction[s], when performed), dual radiotracer (eg, myocardial viability); with concurrently acquired computed tomography transmission scan
78434	Absolute quantitation of myocardial blood flow (AQMBF), positron emission tomography (PET), rest and pharmacologic stress (List separately in addition to code for primary procedure)
HPCP Codes	Description
A9587	Gallium Ga-68, dotatate, diagnostic, 0.1 mCi
A9515	Choline C-11, diagnostic, per study dose up to 20 mCi
A9592	Copper Cu-64, dotatate, diagnostic, 1 mCi
A9593	Gallium Ga-68 PSMA-11, diagnostic, (UCSF), 1 mCi
A9594	Gallium Ga-68 PSMA-11, diagnostic, (UCLA), 1 mCi
A9595	Piflufolastat f-18, diagnostic, 1 mCi
A9596	Gallium Ga-68 gozetotide, diagnostic, (Illuccix), 1 mCi
A9597	Positron emission tomography radiopharmaceutical, diagnostic, for tumor identification, not otherwise classified
A9598	Positron emission tomography radiopharmaceutical, diagnostic, for nontumor identification, not otherwise classified
A9601	Flortaucipir F 18 injection, diagnostic, 1 mCi
Q9982	Flutemetamol F18, diagnostic, per study dose, up to 5 mCi
Q9983	Florbetaben F18, diagnostic, per study dose, up to 8.1 mCi

Non-Medicare Members:

Effective until June 1, 2023

Axumin – PET

HCPSC Codes	Description
A9588	Fluciclovine F-18, diagnostic, 1 mCi

Effective June 1, 2023

Non-Medicare Members:

Axumin – PET is no longer recommended

HCPSC Codes	Description
A9588	Fluciclovine F-18, diagnostic, 1 mCi

Medicare – Considered not covered

Non-Medicare - Considered Medically Necessary when criteria in the applicable policy statements listed above are met

HCPSC Codes	Description
G0235	PET imaging, any site, not otherwise specified
G0252	PET imaging, full and partial-ring PET scanners only, for initial diagnosis of breast cancer and/or surgical planning for breast cancer (e.g., initial staging of axillary lymph nodes)
G0219	PET imaging whole body; melanoma for noncovered indications

***Note:** Codes may not be all-inclusive. Deleted codes and codes not in effect at the time of service may not be covered.

****To verify authorization requirements for a specific code by plan type, please use the [Pre-authorization Code Check](#).**

CPT codes, descriptions and materials are copyrighted by the American Medical Association (AMA). HCPCS codes, descriptions and materials are copyrighted by Centers for Medicare Services (CMS).

Date Created	Date Reviewed	Date Last Revised
12/1997	02/02/2010 ^{MDCRPC} , 12/07/2010 ^{MDCRPC} , 10/04/2011 ^{MDCRPC} , 08/07/2012 ^{MDCRPC} , 11/06/2012 ^{MDCRPC} , 09/03/2013 ^{MPC} , 12/03/2013 ^{MPC} , 12/02/2014 ^{MPC} , 10/06/2015 ^{MPC} , 08/02/2016 ^{MPC} , 06/06/2017 ^{MPC} , 04/03/2018 ^{MPC} , 04/02/2019 ^{MPC} , 04/07/2020 ^{MPC} , 04/06/2021 ^{MPC} , 04/05/2022 ^{MPC} , 04/04/2023 ^{MPC}	04/18/2023

^{MDCRPC} Medical Director Clinical Review and Policy Committee

^{MPC} Medical Policy Committee

Revision History	Description
08/05/2015	Added Medicare Link to NCD 210.3 for Colorectal Cancer Screening Test
01/03/2017	Added Coverage Article A54668
05/01/2018	MPC approved to adopt Axumin PET non-coverage criteria
10/02/2018	Updated guidelines for head and neck cancers
12/7/2018	Added clarification about Medicare Radiopharmaceuticals
02/05/2019	MPC approved to adopt coverage criteria for Axumin Injection for PET scan. Added to background MTAC review from 01/2019.
03/05/2019	Added indications for Gastroenteropancreatic Neuroendocrine Tumors (GEP-NET)
04/02/2019	MPC approved criteria for Axumin PET for prostate cancer
05/07/2019	MPC approved to adopt criteria for Cardiac PET
01/27/2020	Updated Site of Service for Gastroenteropancreatic Neuroendocrine Tumors (GEP-NET)
05/05/2020	MPC approved to adopt updates for cardiac sarcoidosis
06/01/2021	MPC approved to endorse the recommendations for PET imaging using somatostatin receptor (SSR)-PET for neuroendocrine tumors from the National Comprehensive Cancer Network® (NCCN) Guideline for Neuroendocrine and Adrenal Tumors . Also, removed reference to using Swedish as the site of service and added Kaiser Permanente locations. Requires 60-day notice, effective date 11/01/2021.
01/07/2022	Listed covered radiopharmaceuticals in Medicare section as per LCA A54668. Added Gallium GA-68 PSMA-11 and Piflufolastat F-18 (PSMA PET for prostate) as currently not medically necessary for non-Medicare.

01/31/2022	Updated NCD 220.6.19 link
12/06/2022	Care Delivery Medical Necessity Review for ENT/OTO and Pulmonary audit has been reviewed; prior authorization with no medical review has been awarded for another year
01/10/2023	MPC approved to adopt coverage for Whole Body CT for Multiple Myeloma; 60-day notice required, effective June 1, 2023.
01/10/2023	MPC approved to adopt coverage for PET-PSMA; 60-day notice required, effective June 1, 2023. PSMA PET located in separate criteria.
1/23/2023	Added new codes A9601, A9596 effective 7/1/2023
03/03/2023	Added New HCPC code A9602 effective 10/01/2022
04/18/2023	Clarified language for imaging modality for Multiple Myeloma